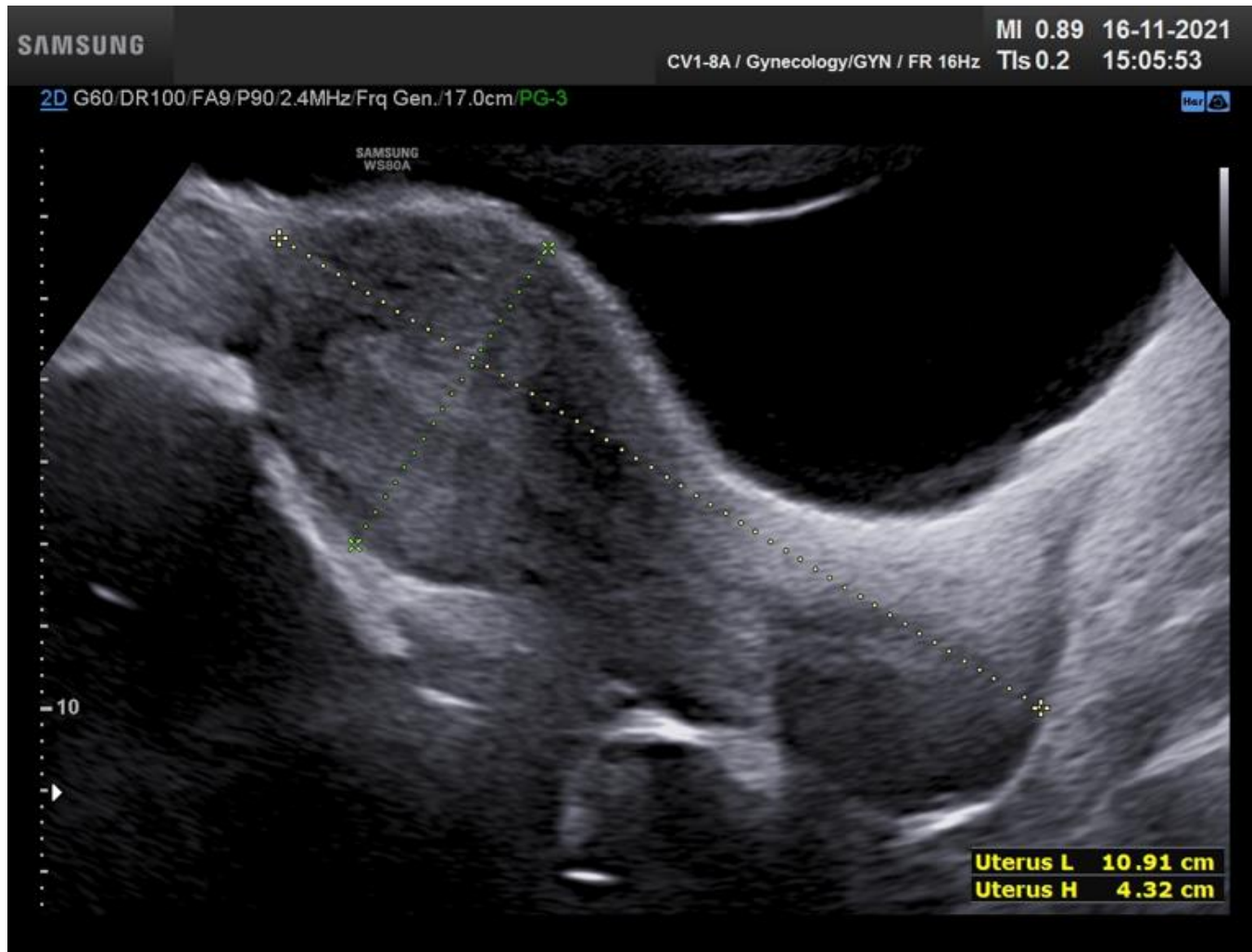

# Gynaecologie

Uterus sagittaal (TA)

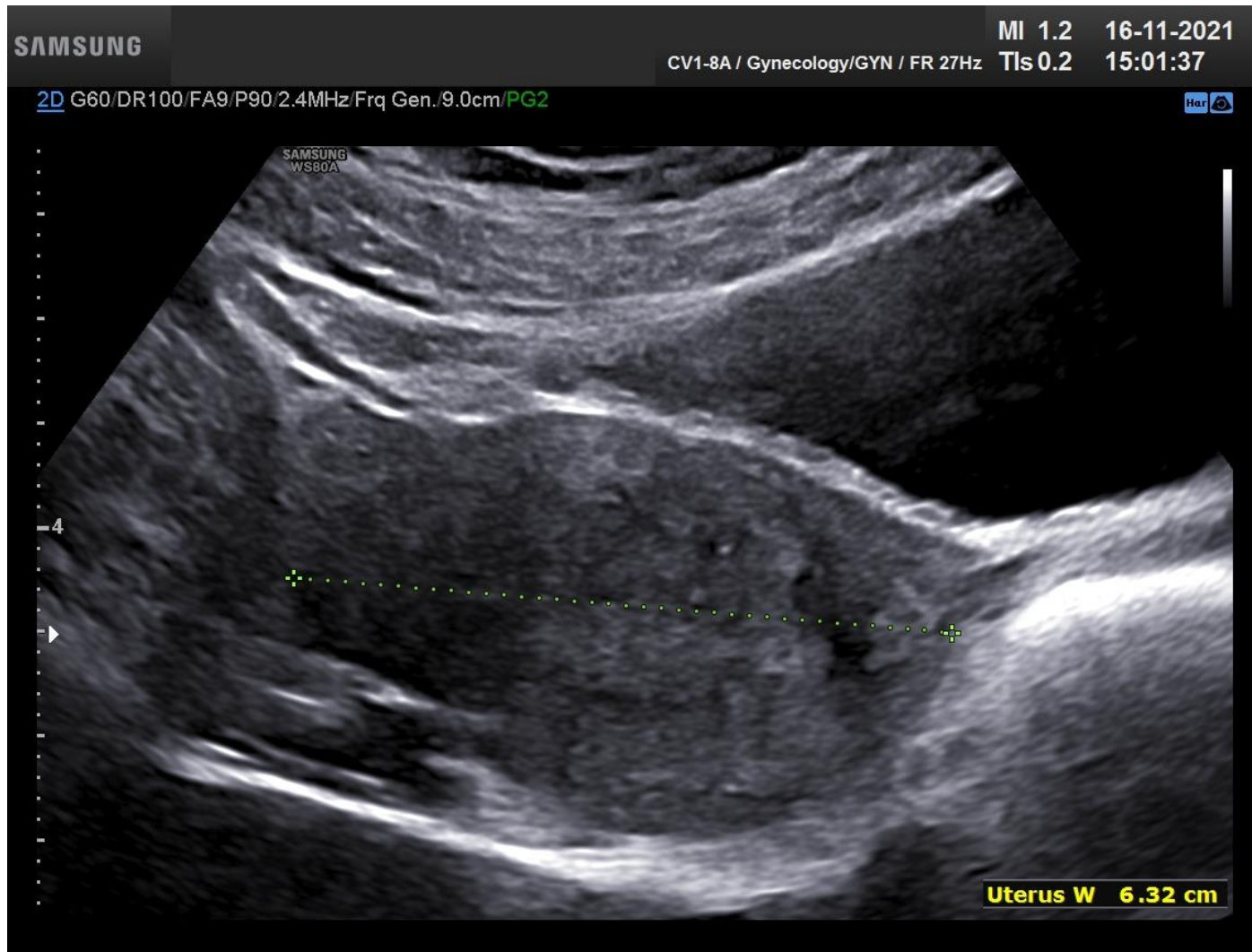
Foto 1a



# Gynaecologie

Uterus transversaal (TA)

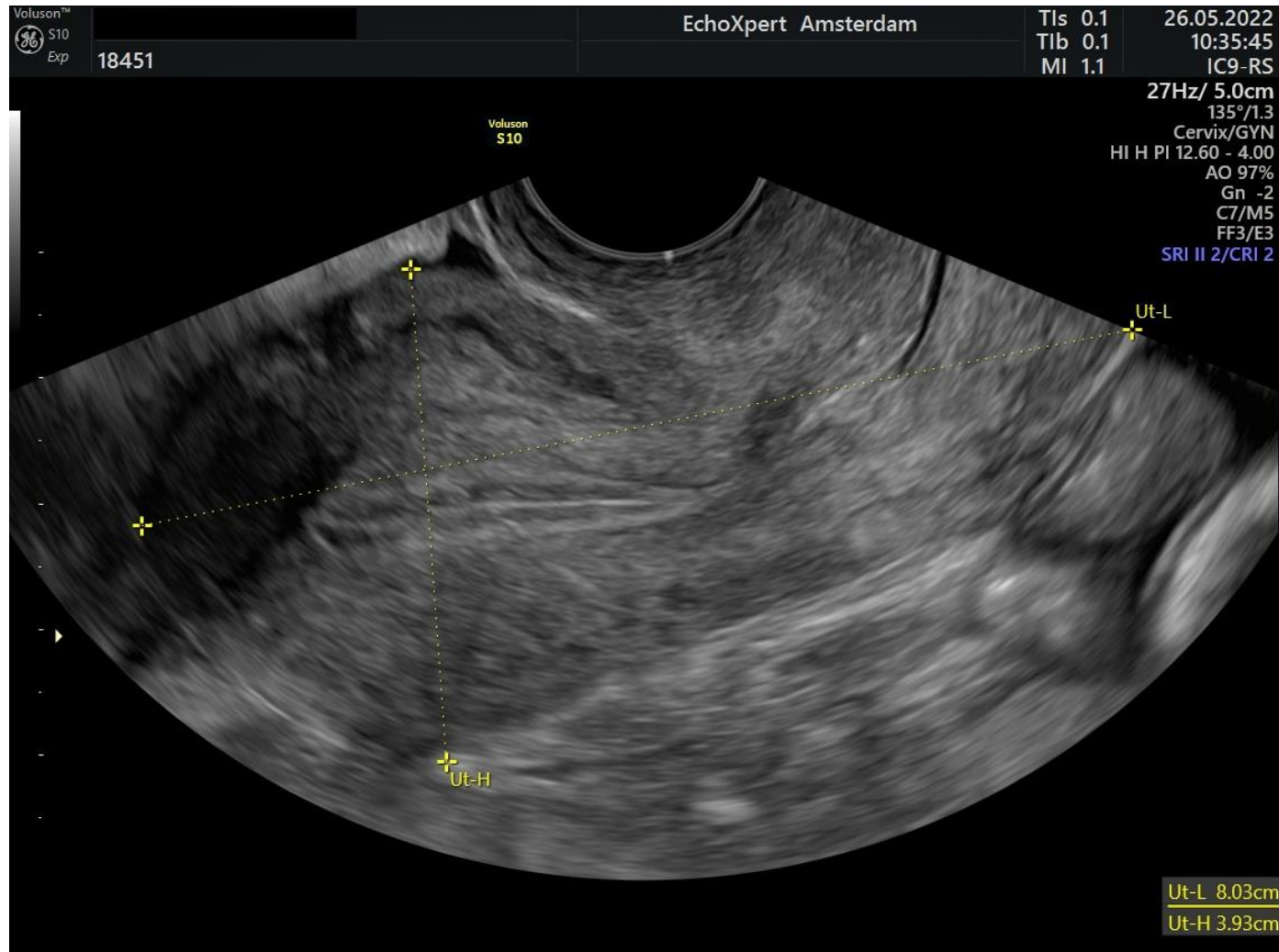
Foto 1b



# Gynaecologie

Uterus sagittaal (TV)

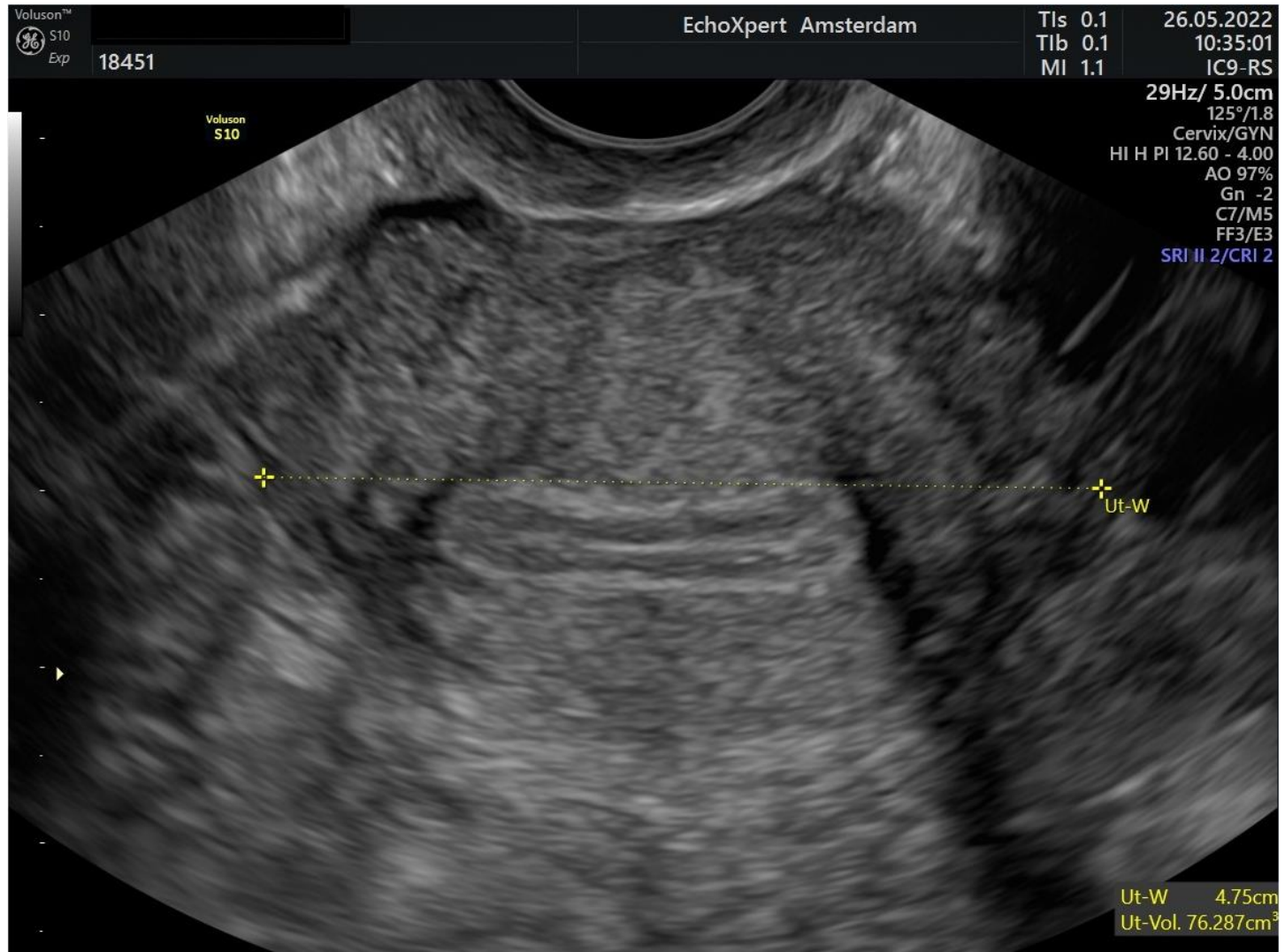
Foto 2a/3a



# Gynaecologie

Uterus transversaal (TV)

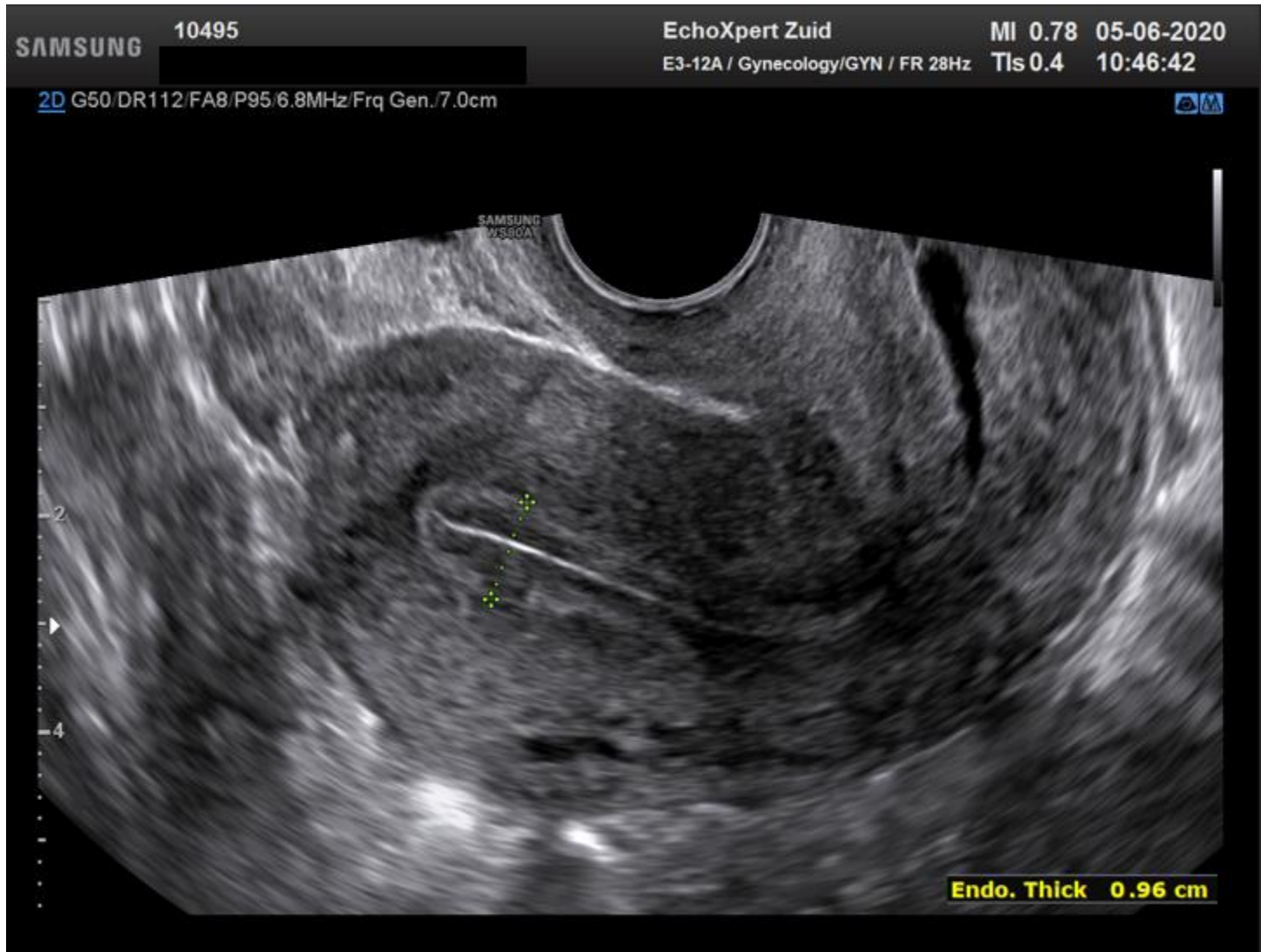
Foto 2b/3b



# Gynaecologie

Endometrium (TV)

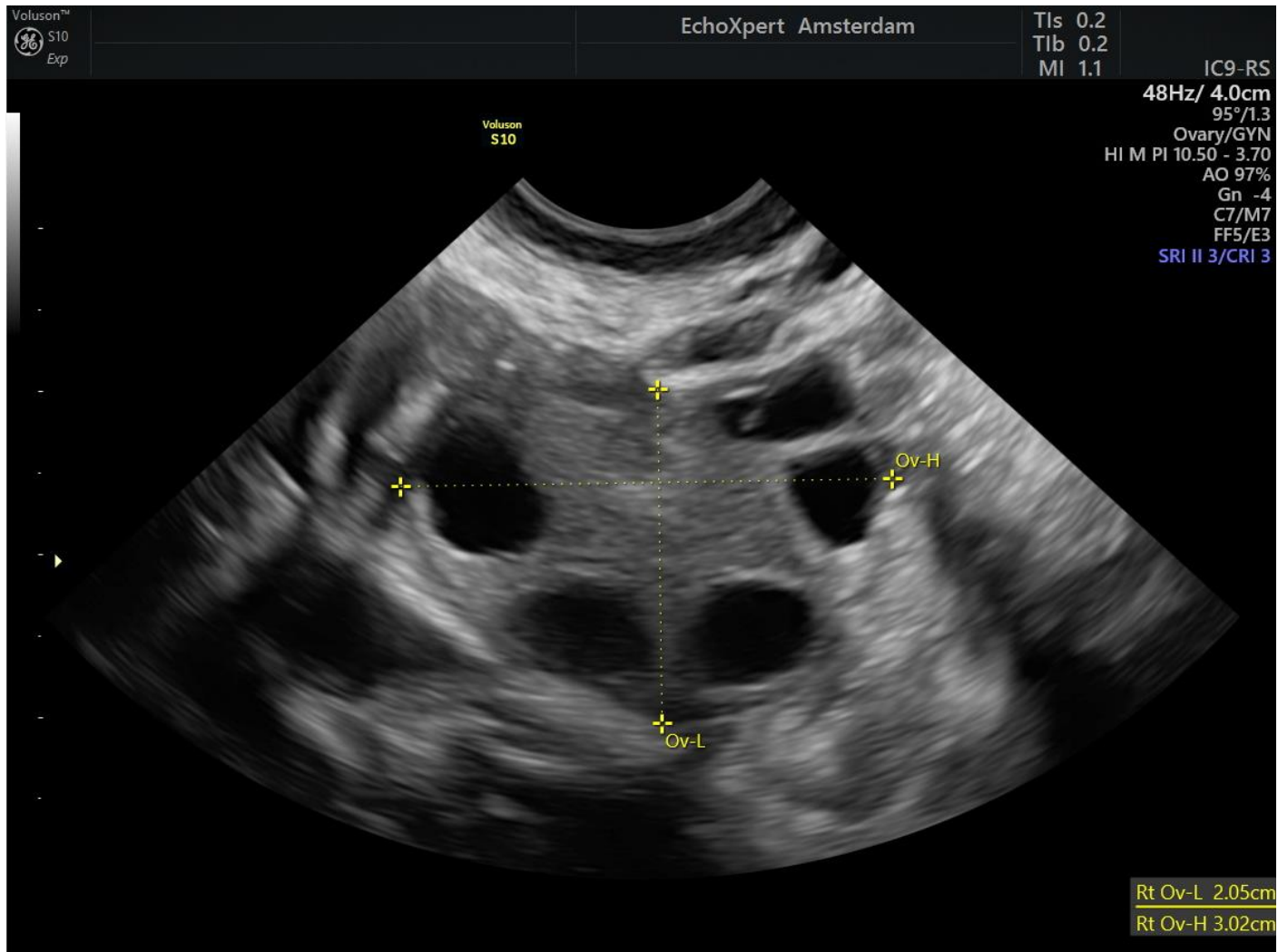
Foto 4/5



# Gynaecologie

Ovaria sagittaal (TV)

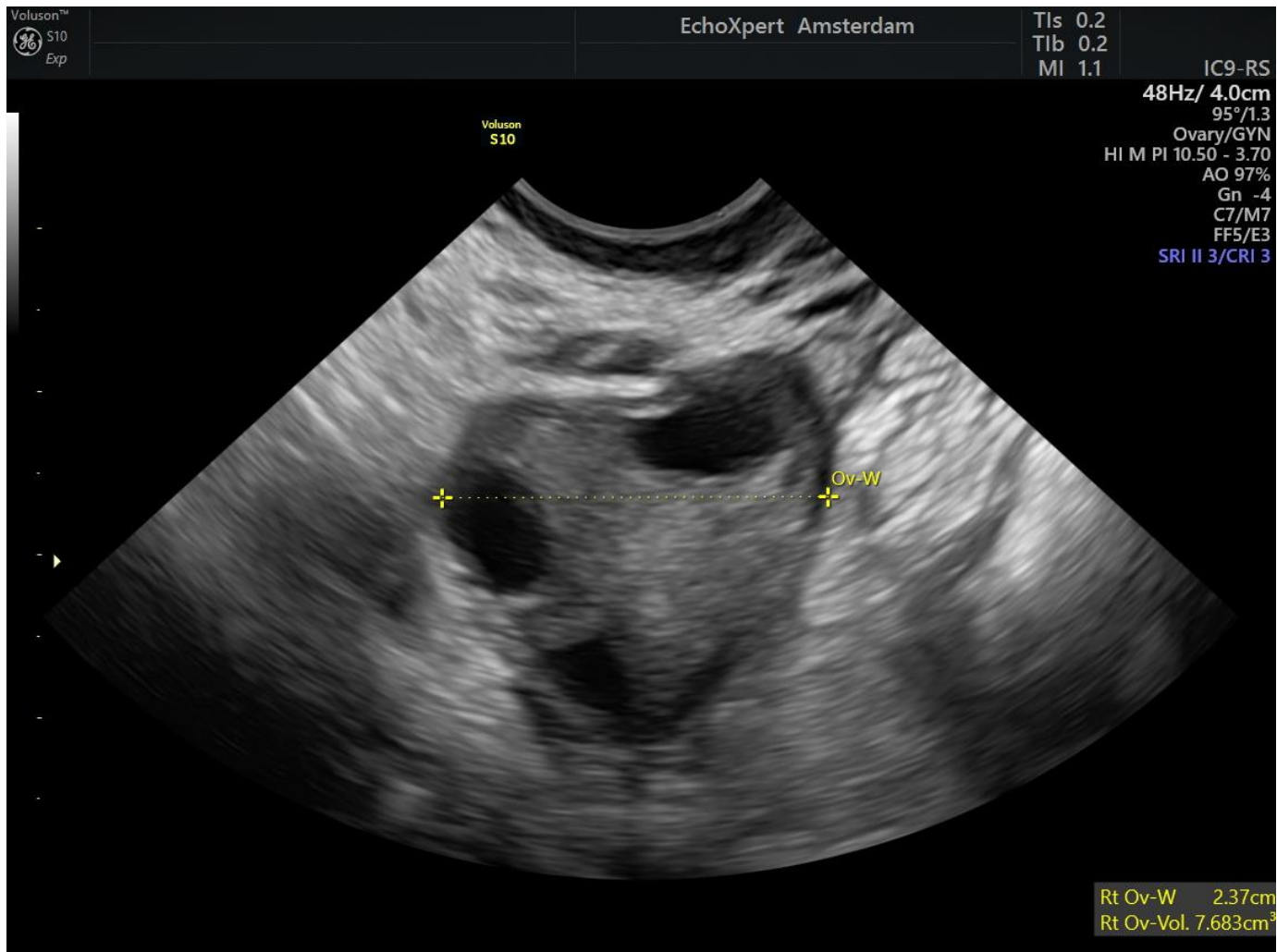
Foto 6a/6c/7a/7c



# Gynaecologie

Ovaria transversaal (TV)

Foto 6b/6d/7b/7d

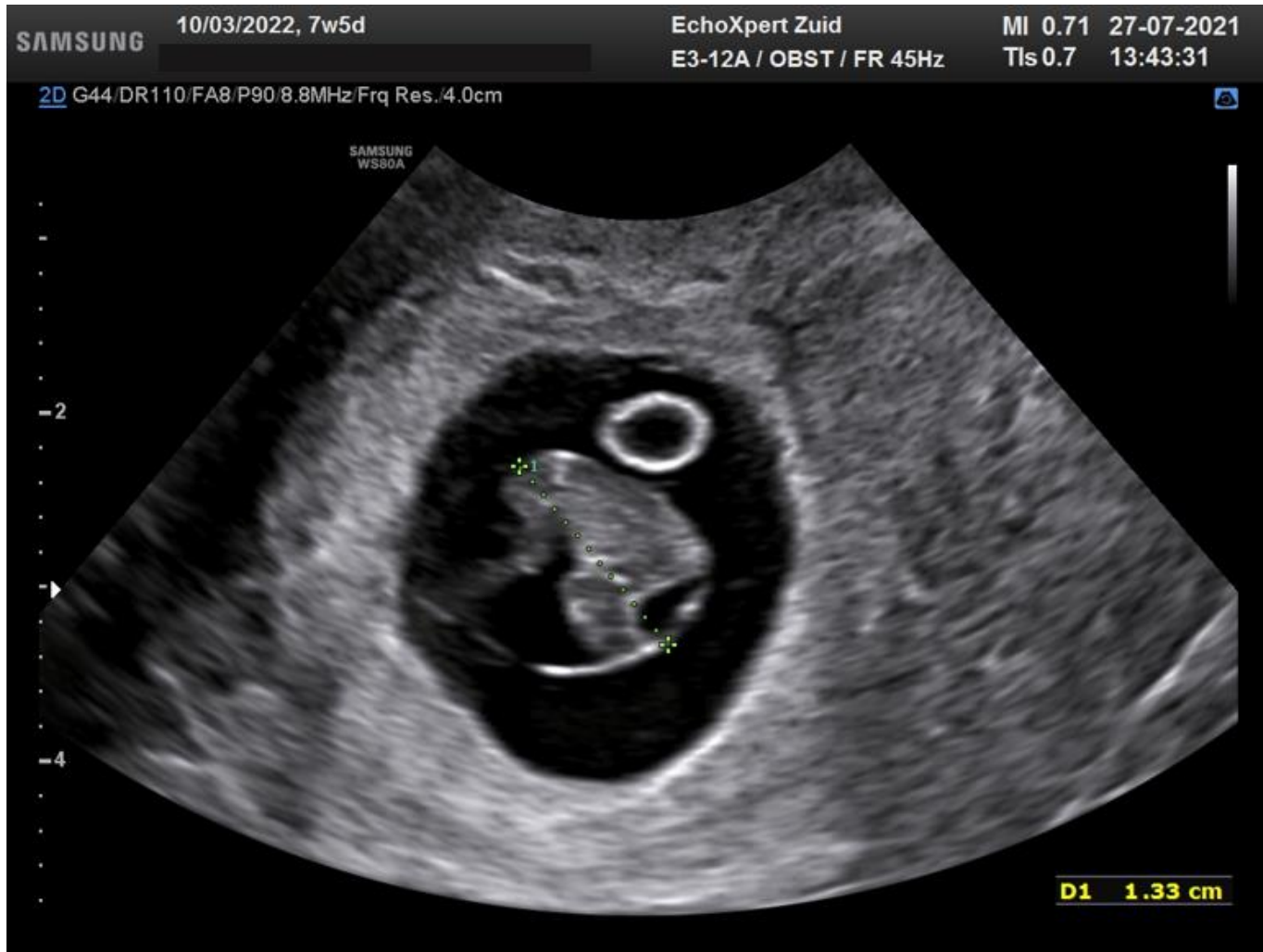

# 1<sup>e</sup> trimester CRL en overzicht

CRL 7+ wk (TV)

Foto 8/9

CRL sagittaal

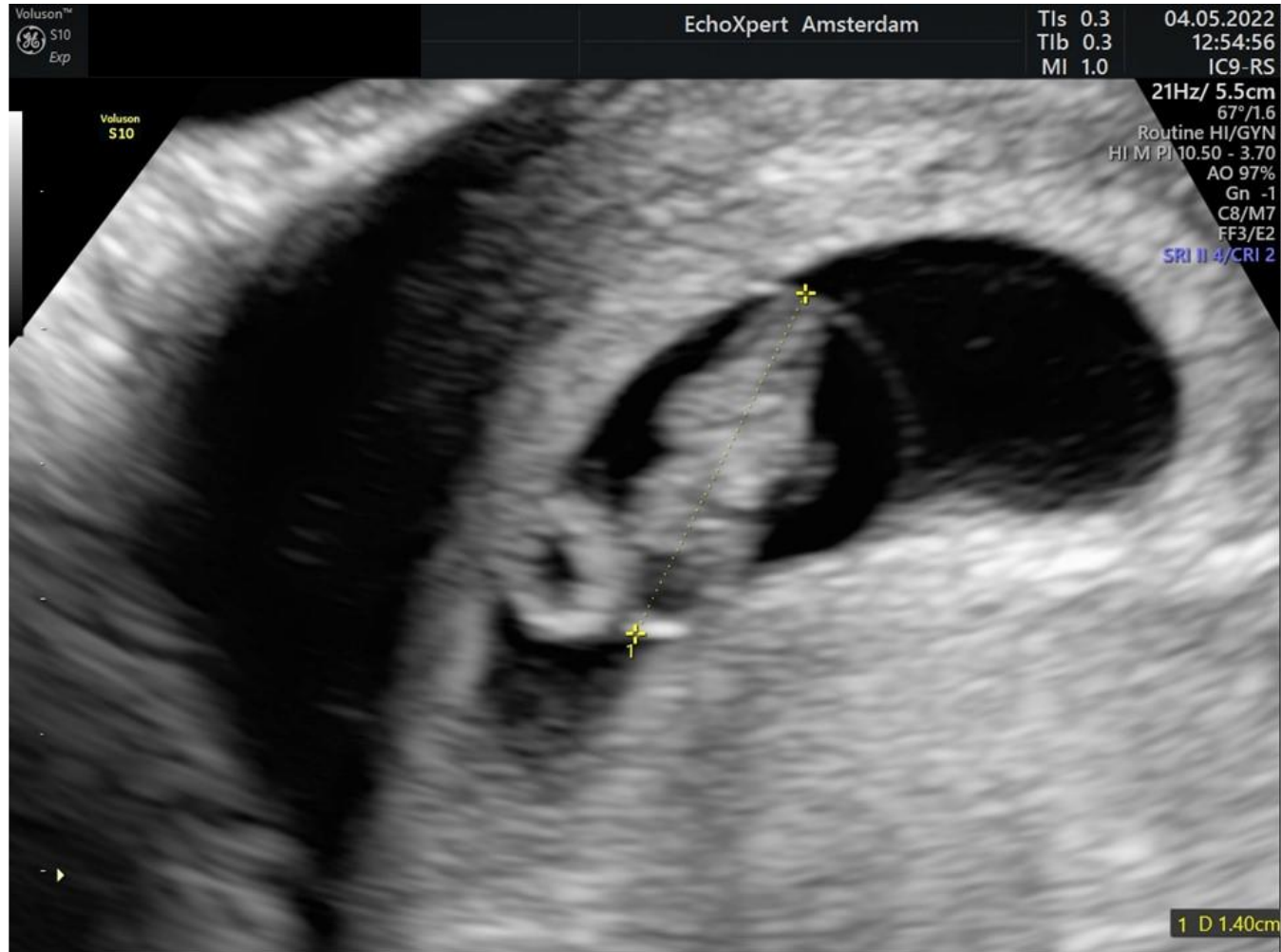




# CRL en overzicht

CRL 7+ wk (TV)

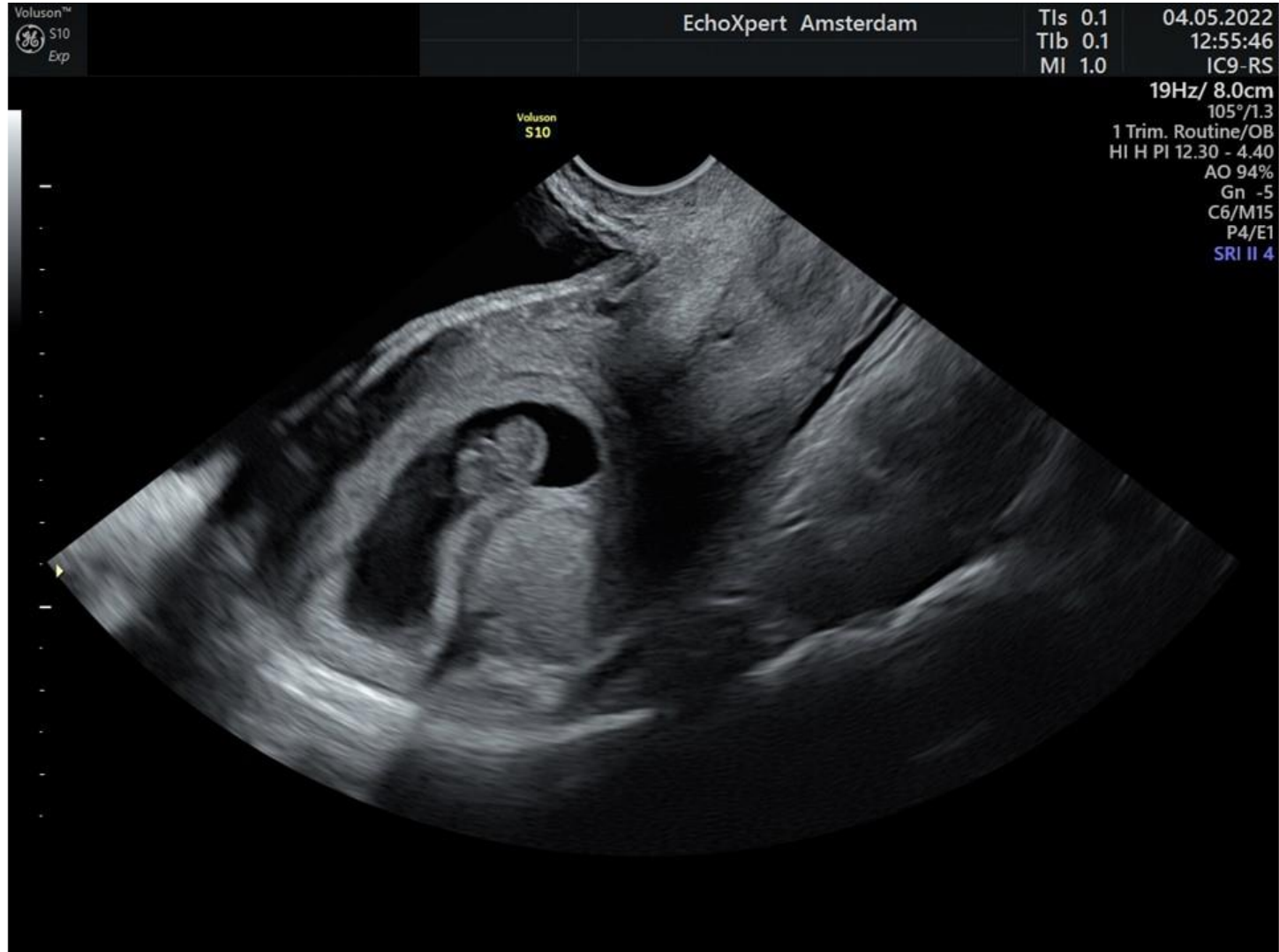
Foto 8/9  
Of CRL coronaal



# CRL en overzicht

Overzicht uterus met IUG 7+ wk (TV)

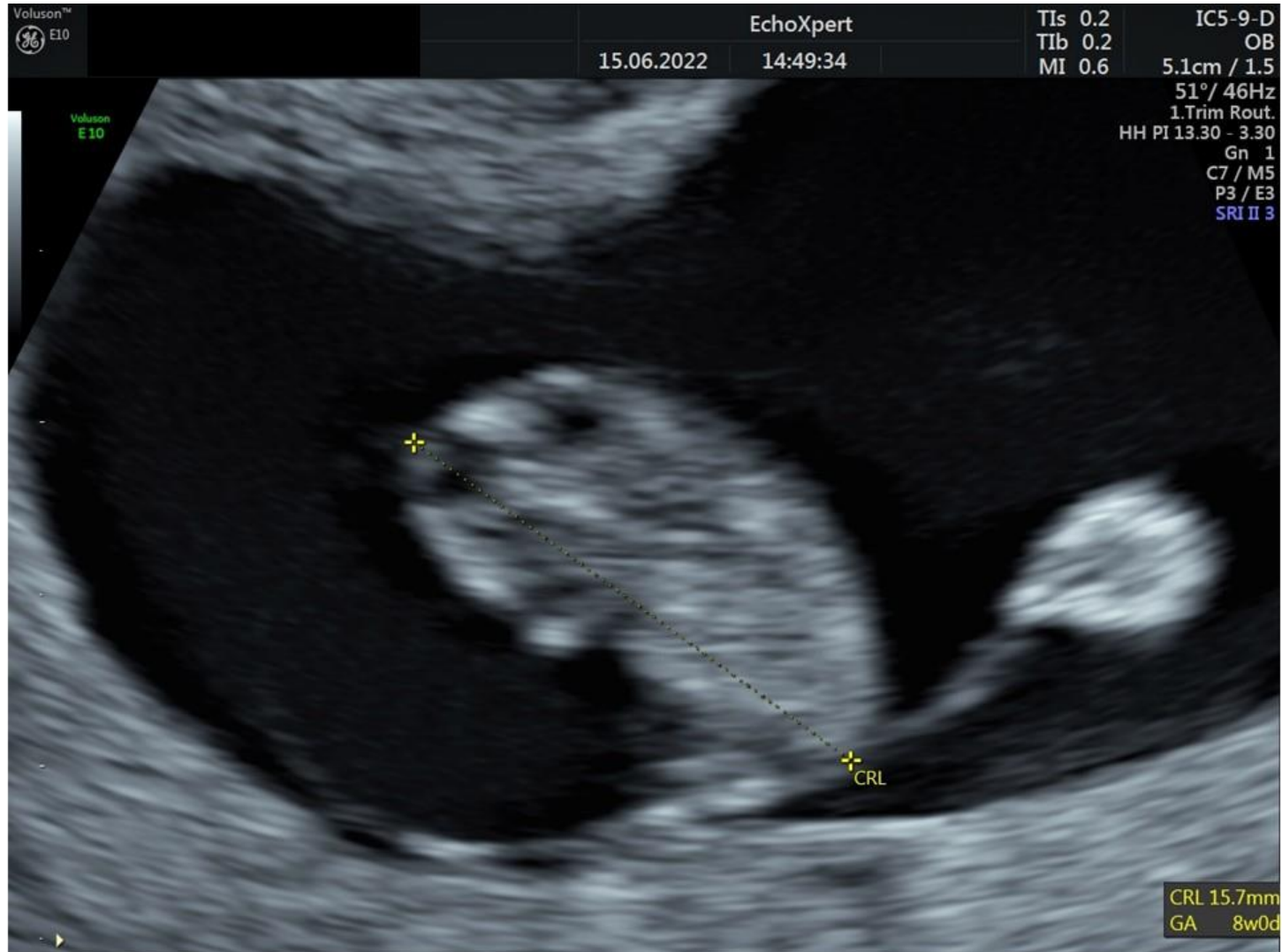Foto 10



# CRL en overzicht

CRL 8+ wk (TV)

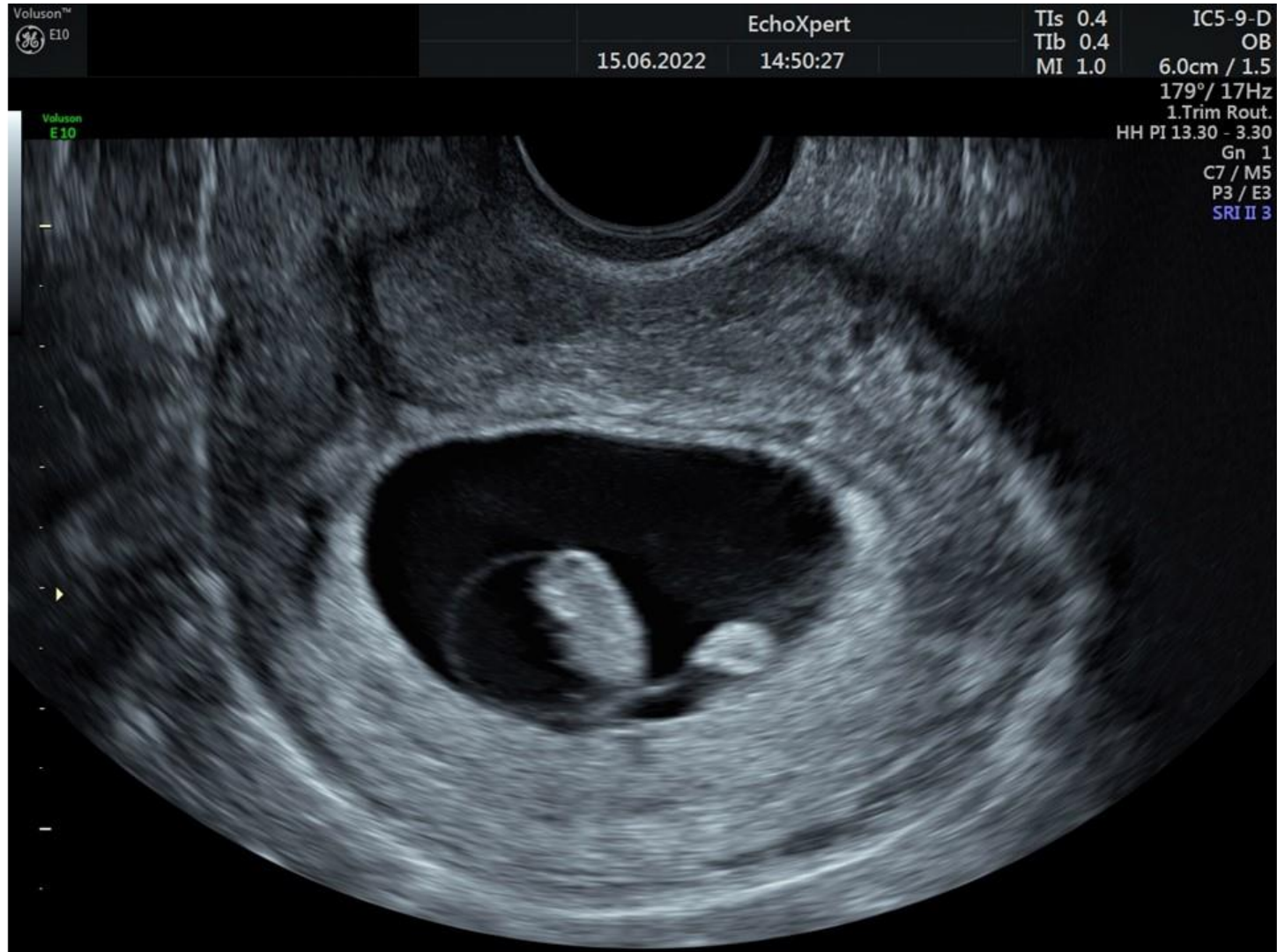Foto 11/12



# CRL en overzicht

Overzicht uterus met IUG 8+ wk (TV)

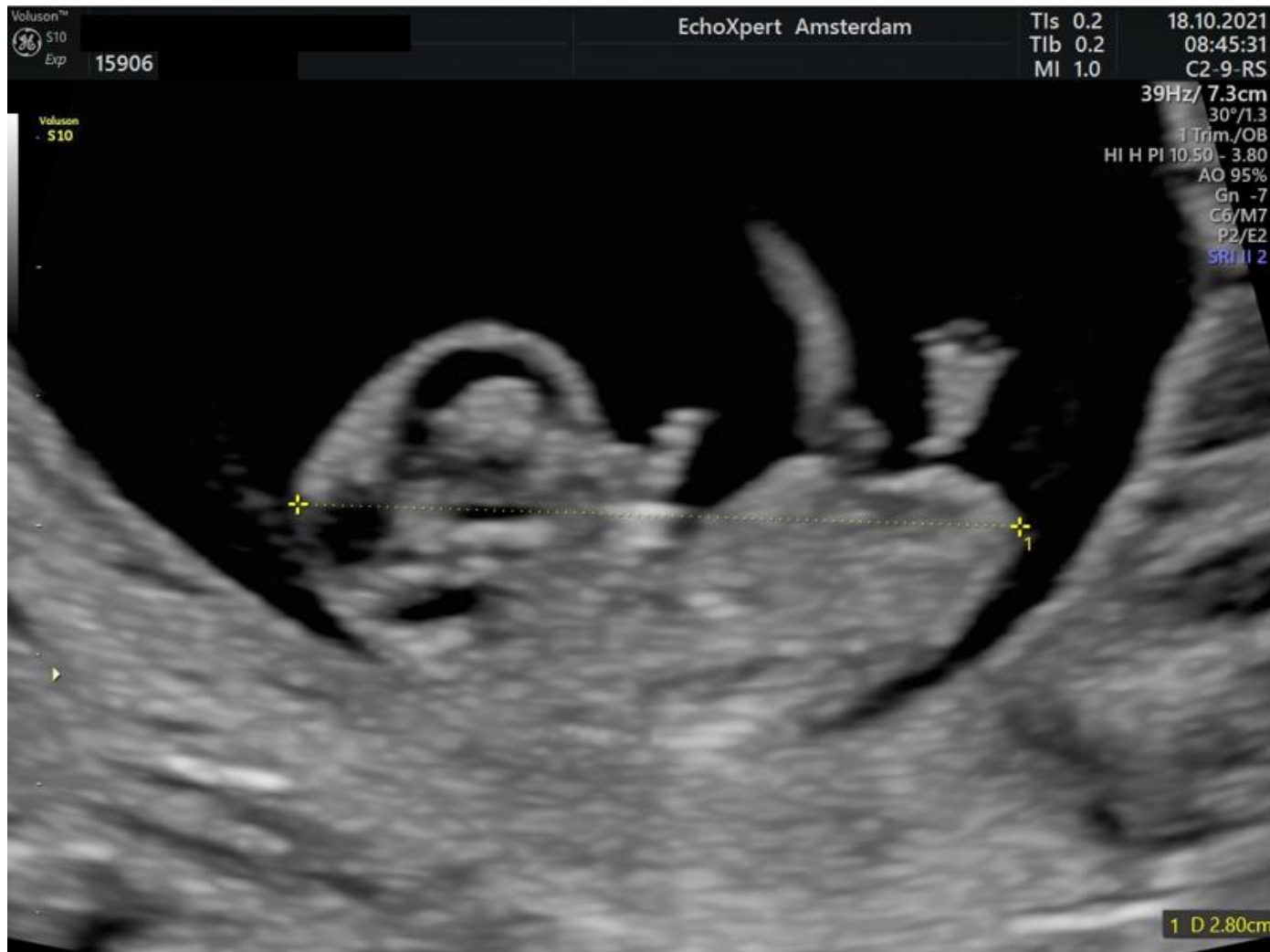Foto 13



# CRL en overzicht

CRL 9+ wk (TV)

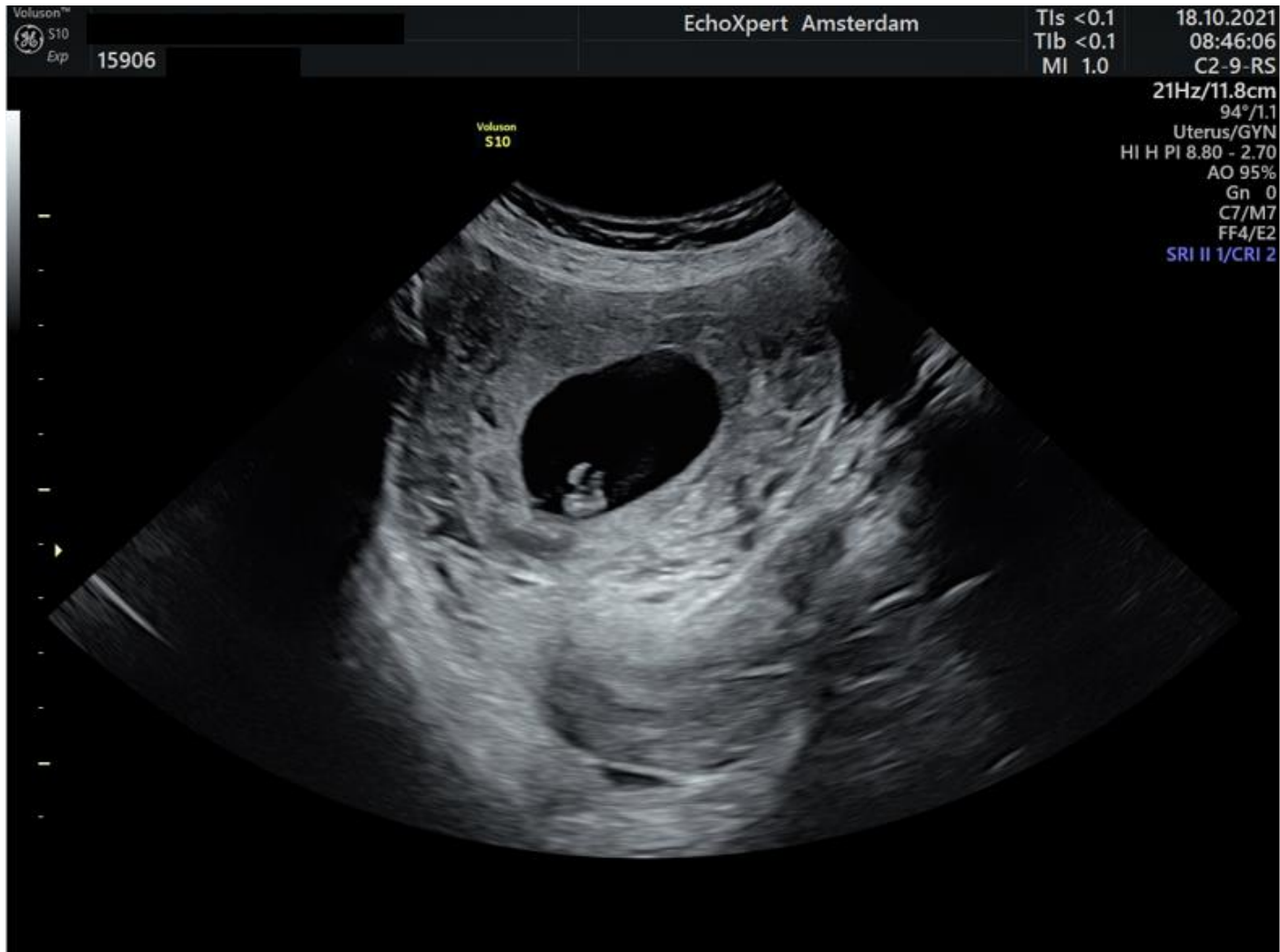
Foto 14/15



# CRL en overzicht

Overzicht uterus met IUG 9+ wk (TV)

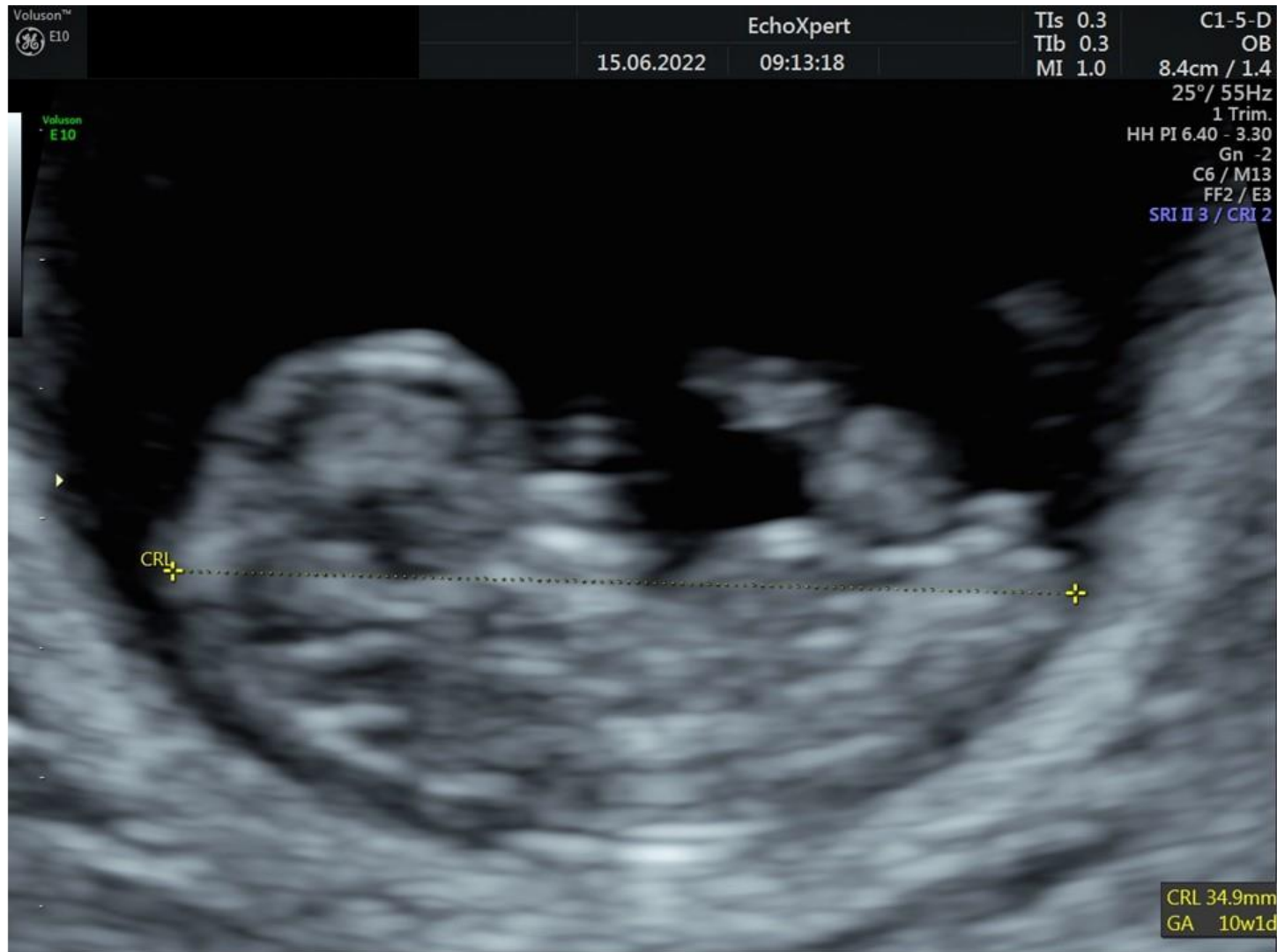Foto 16



# CRL en overzicht

CRL 10+ wk (TV/TA)

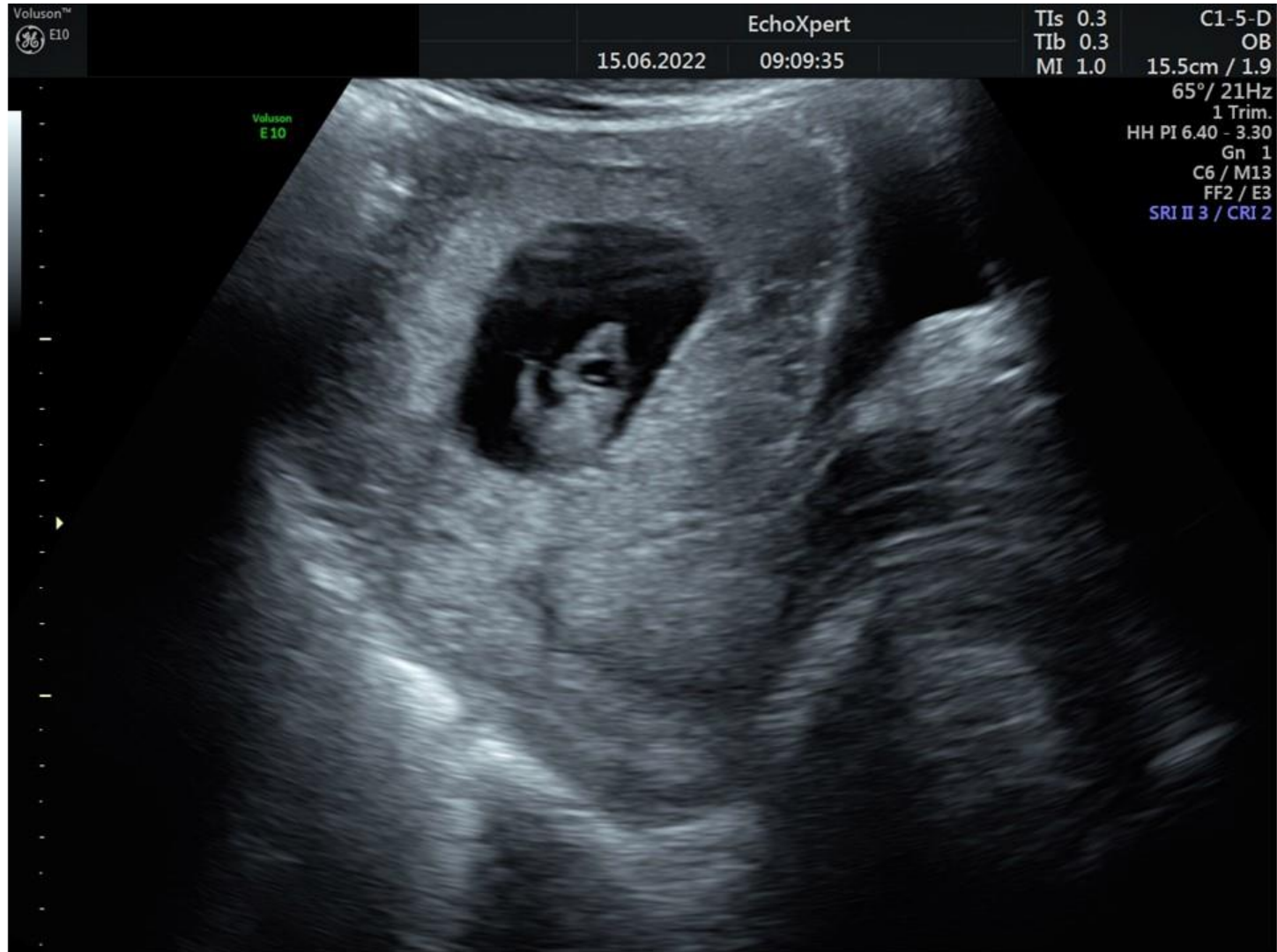Foto 17/18



# CRL en overzicht

Overzicht uterus met IUG 10+ wk (TV/TA)

Foto 19

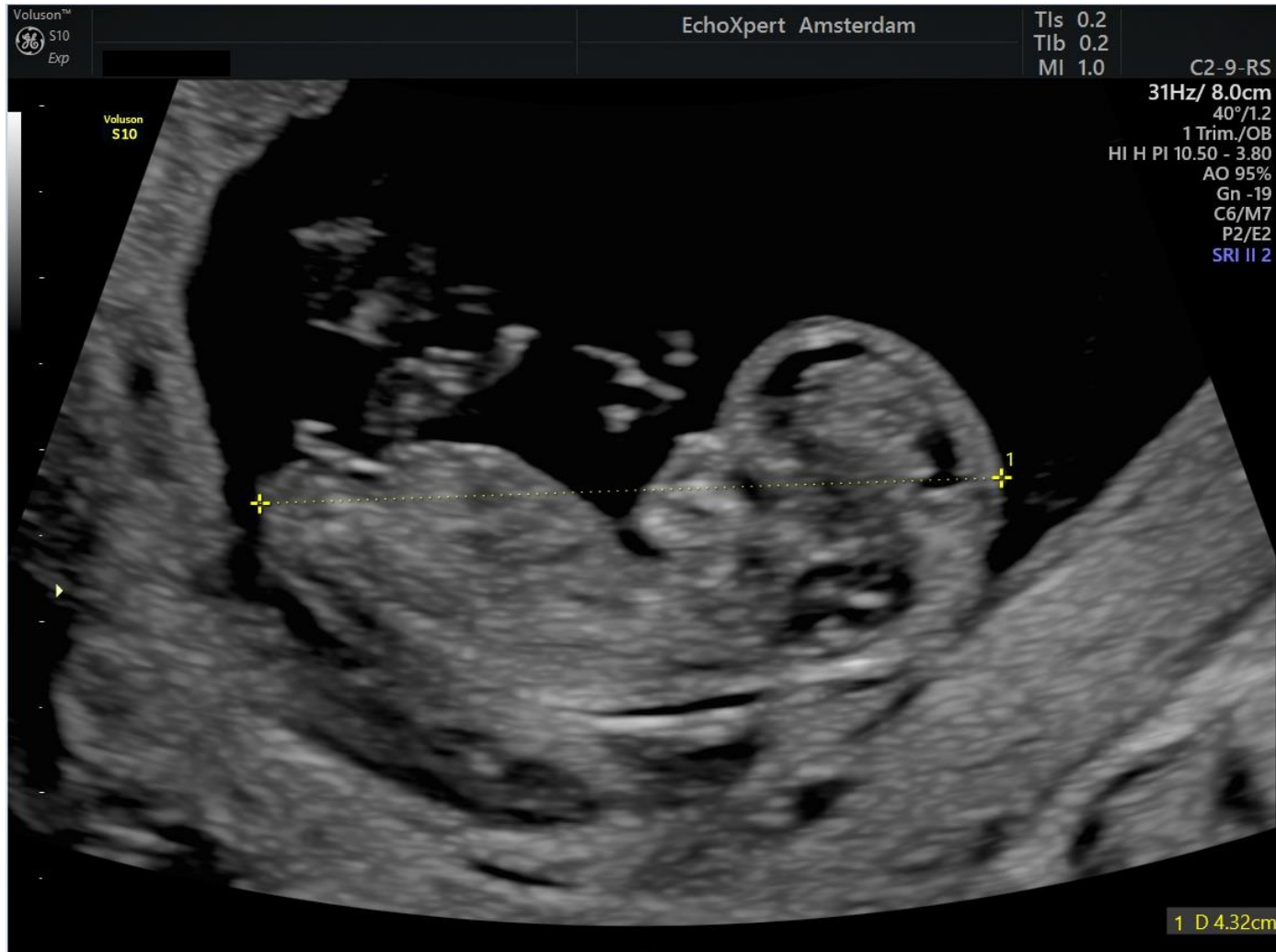



# 1<sup>e</sup> trimestre

CRL 11+ wk (TA)

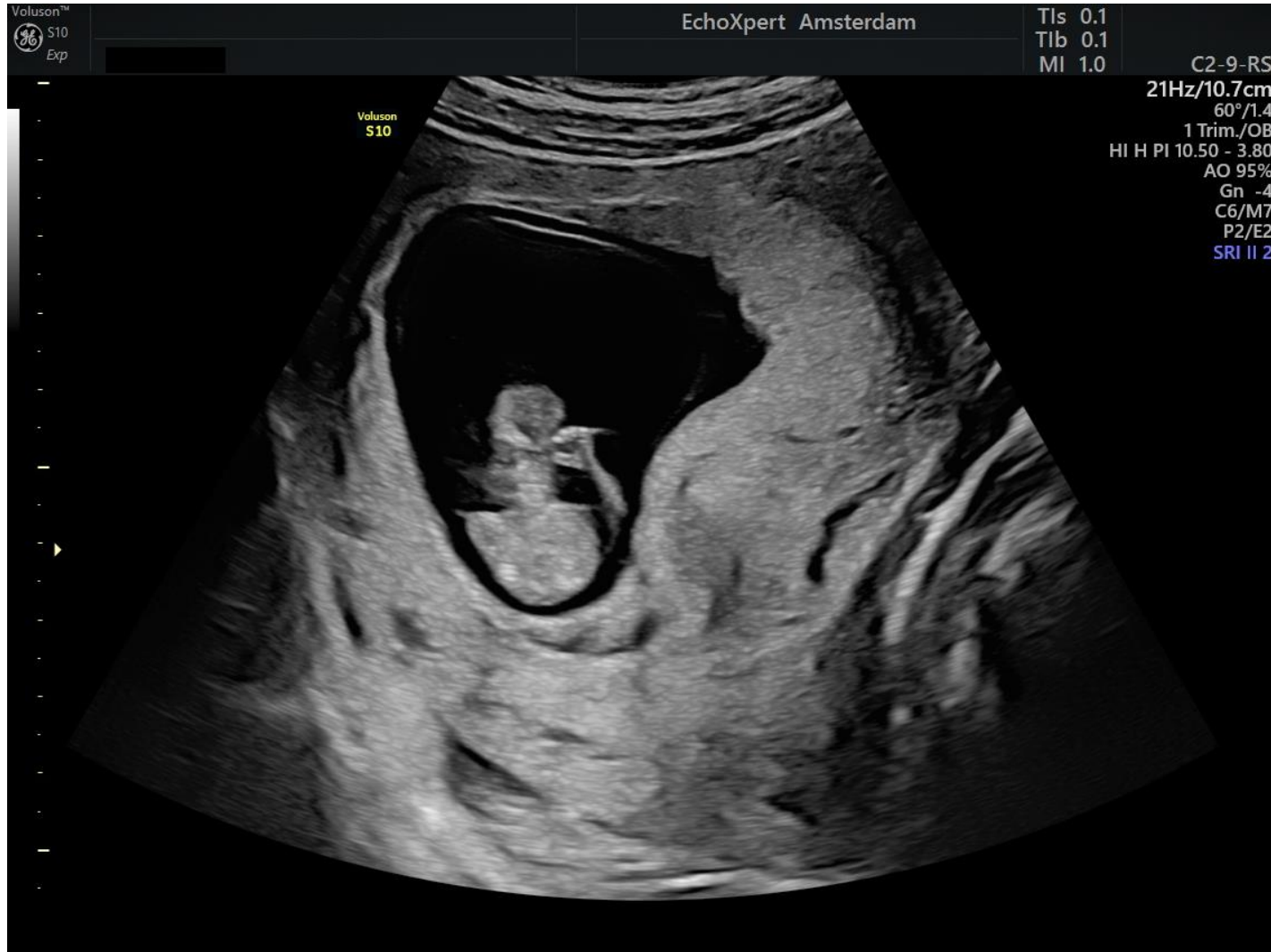Foto 20/21



# CRL en overzicht

Overzicht uterus met IUG 11+ wk (TA)

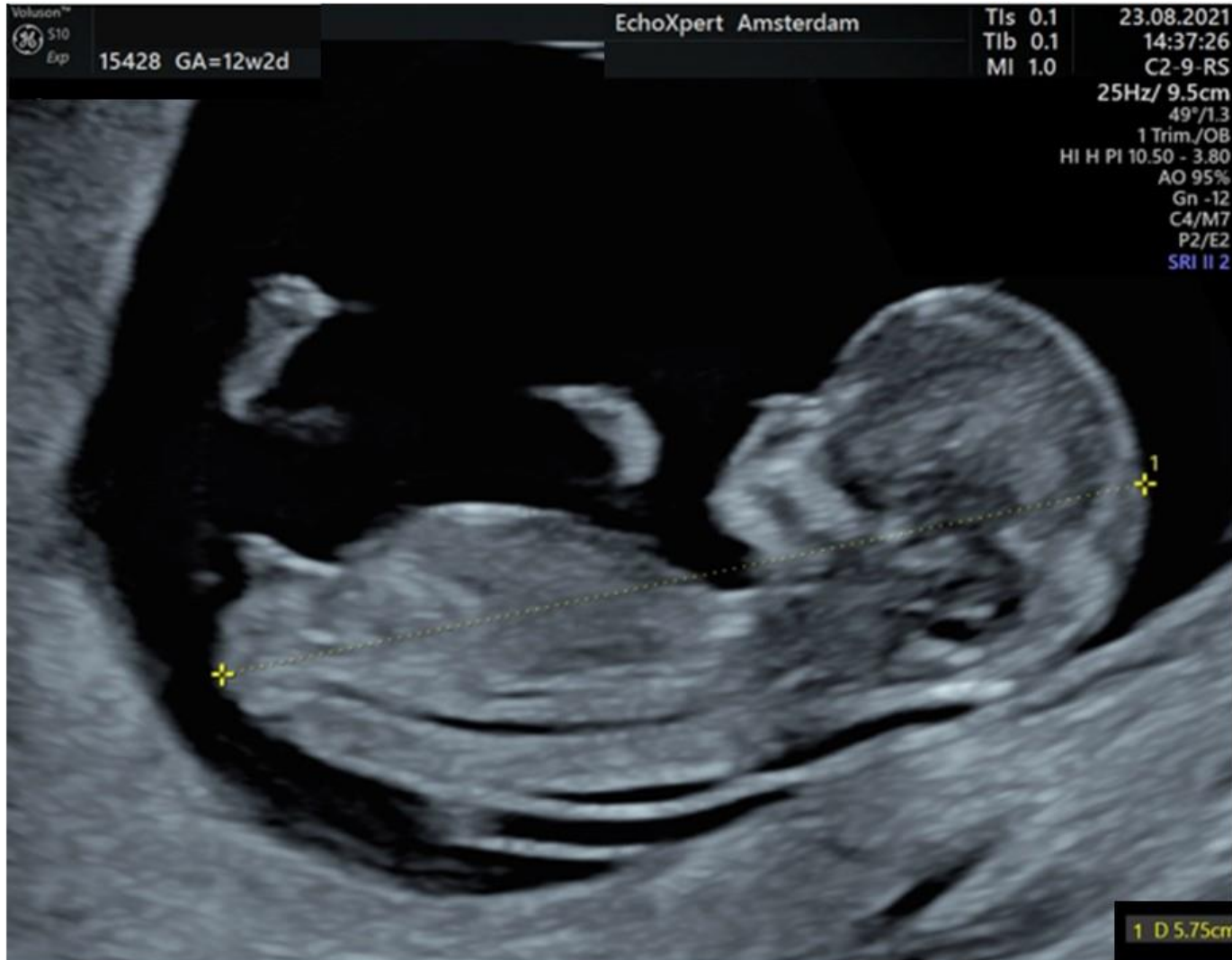Foto 22



# CRL en overzicht

CRL 12+ wk (TA)

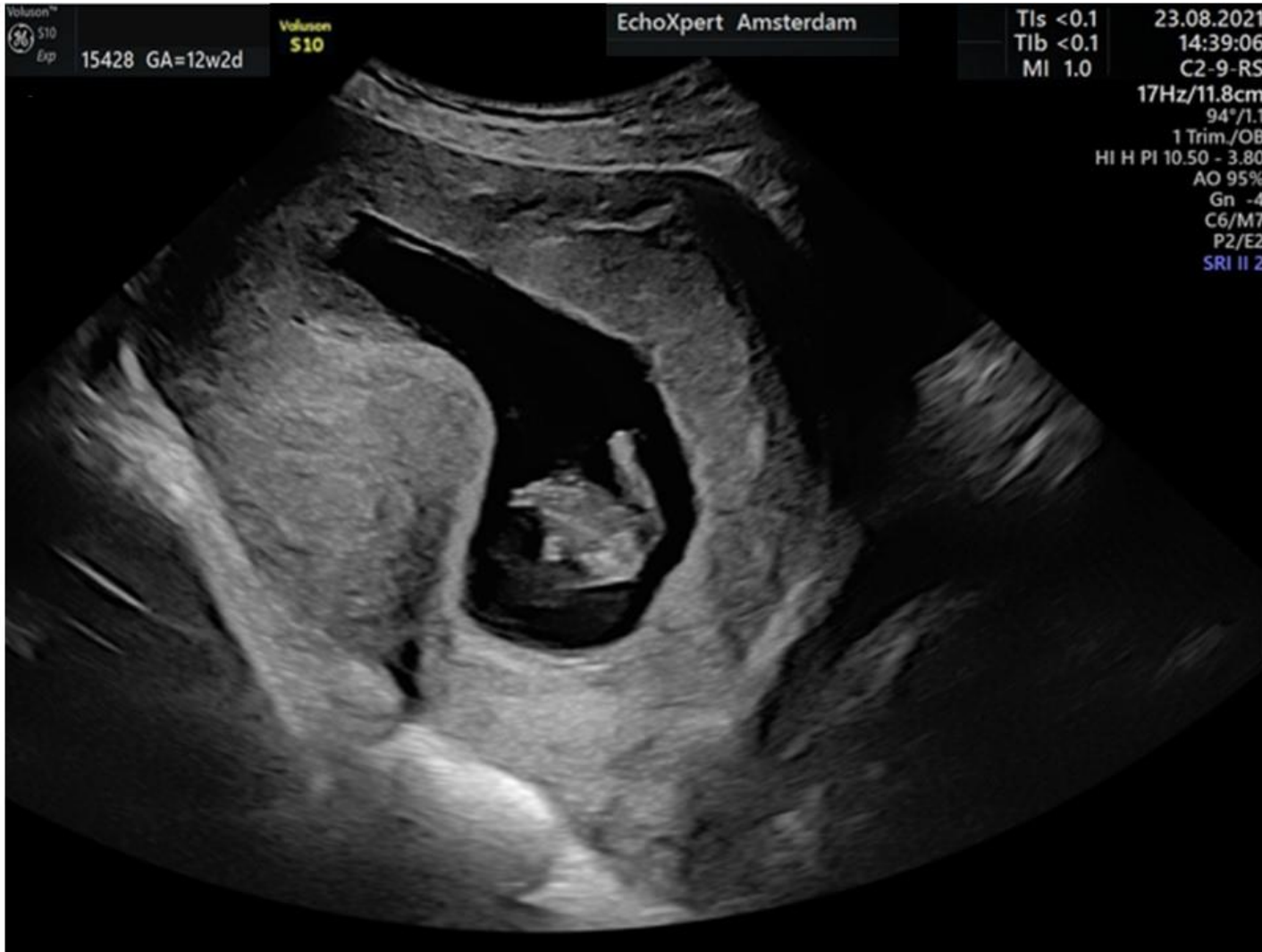Foto 23/24



# CRL en overzicht

Overzicht uterus met IUG 12+ wk (TA)

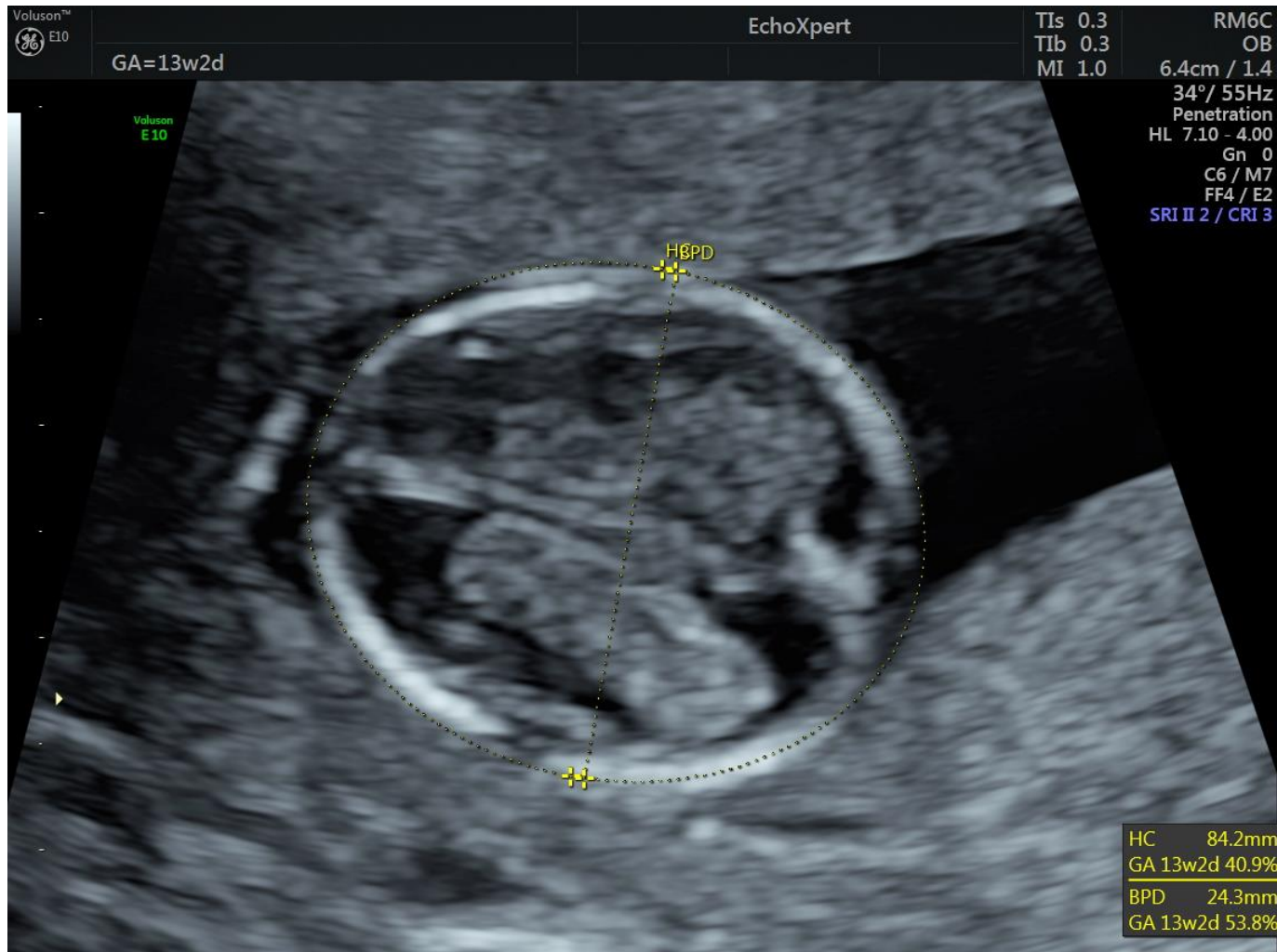
Foto 25



# HC / DBP

HC / DBP 13 - 14 wk

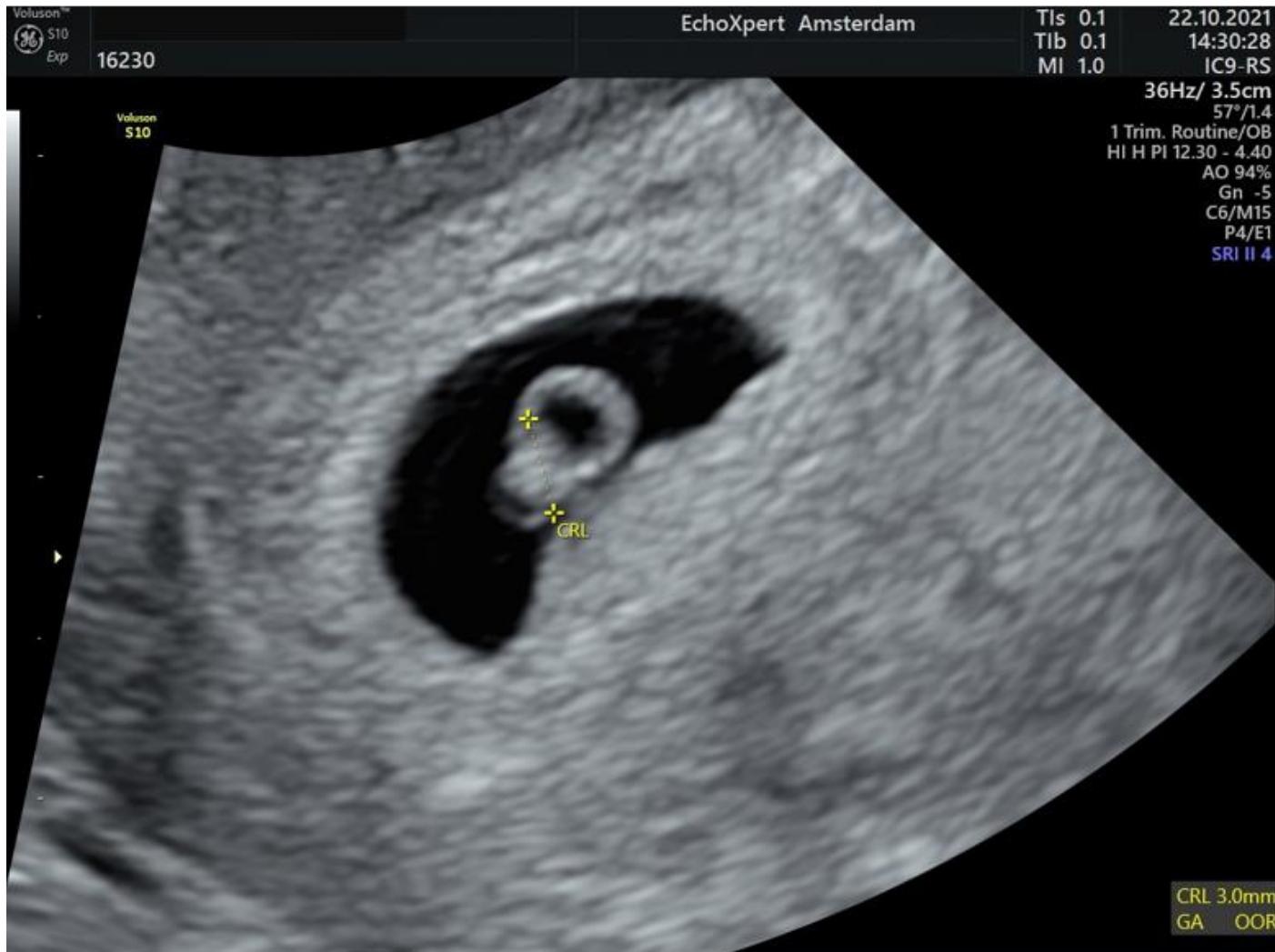Foto 26/27



# Dooierzak / vruchtzak

Dooierzak 5+ wk (TV)

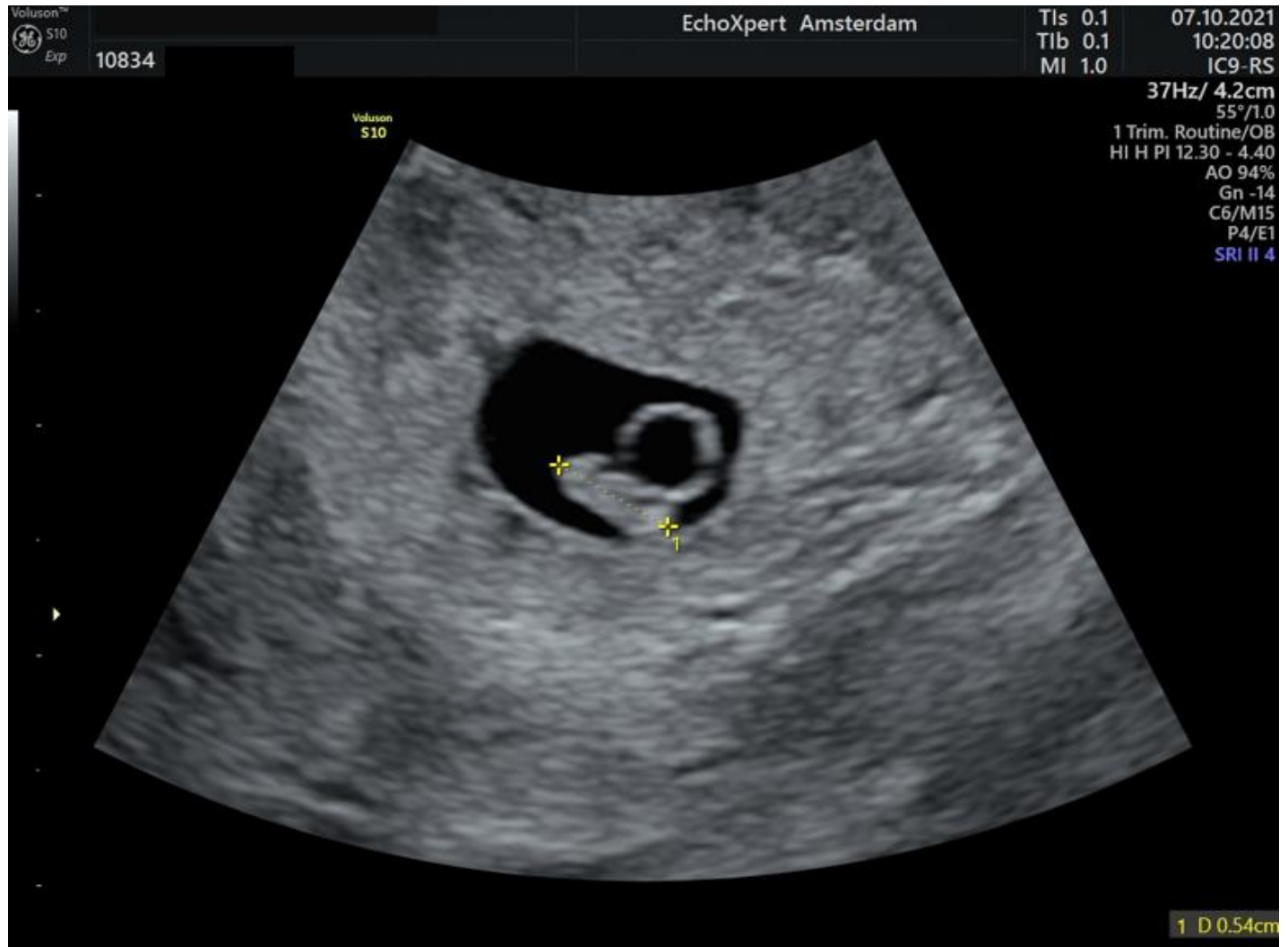Foto 28



# Dooierzak / vruchtzak

Dooierzak 6+ wk (TV)

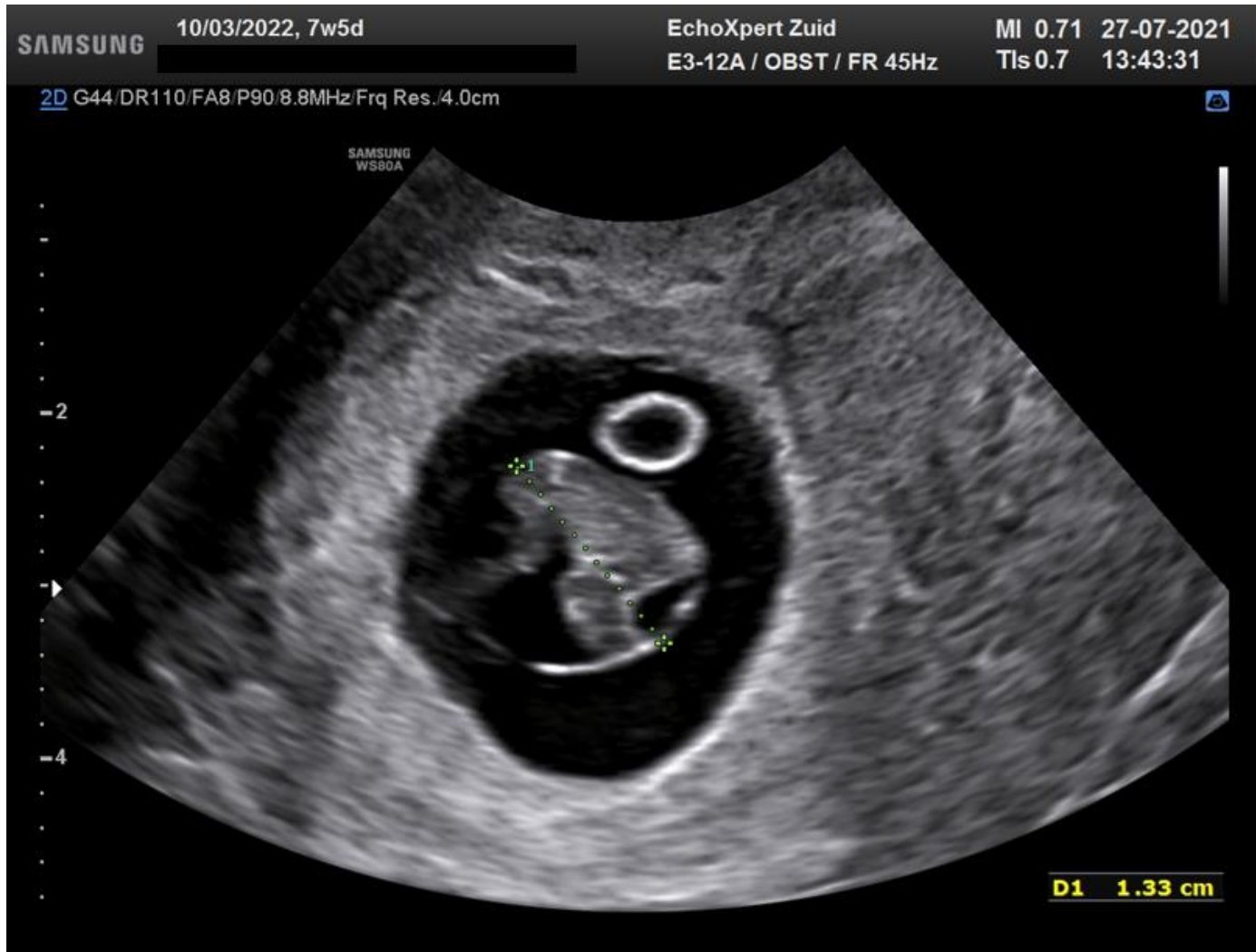Foto 29



# Dooierzak / vruchtzak

Dooierzak en amnionvlies 7+ wk (TV)

Foto 30a/b

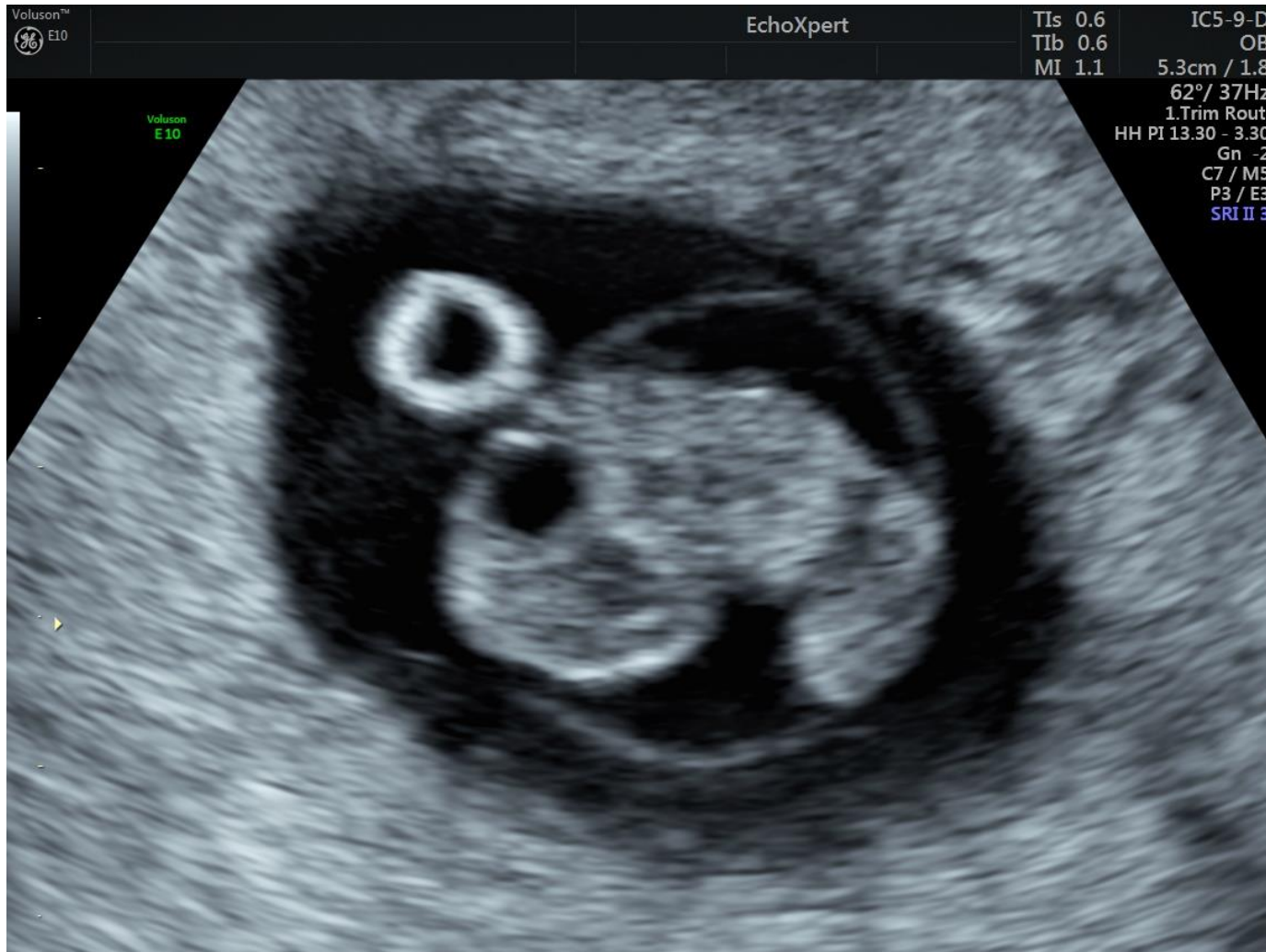




# Dooierzak / vruchtzak

Dooierzak en amnionvlies 8+ wk (TV)

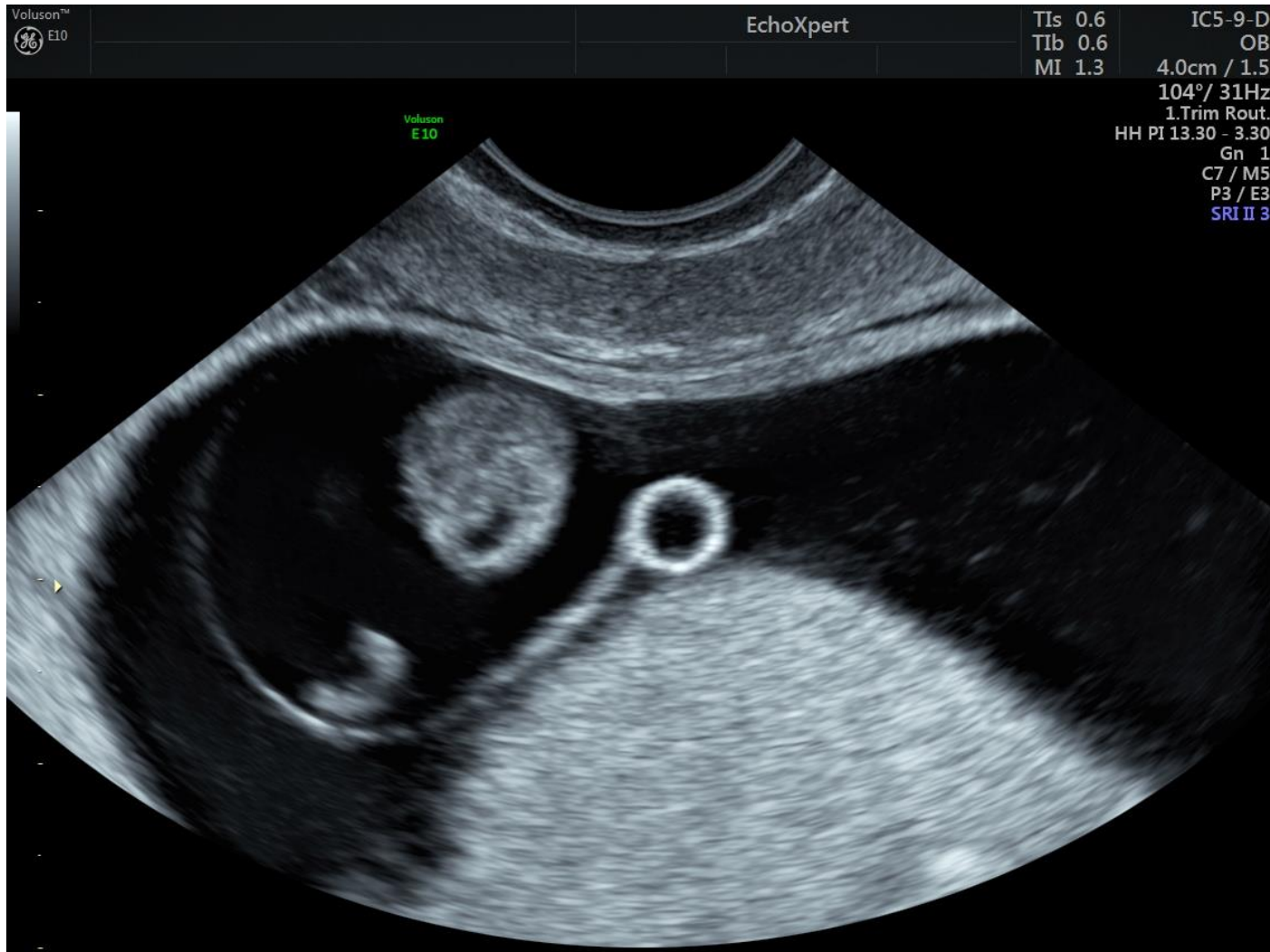Foto 31a/b



# Dooierzak / vruchtzak

Dooierzak en amnionvlies 9+ wk (TV)

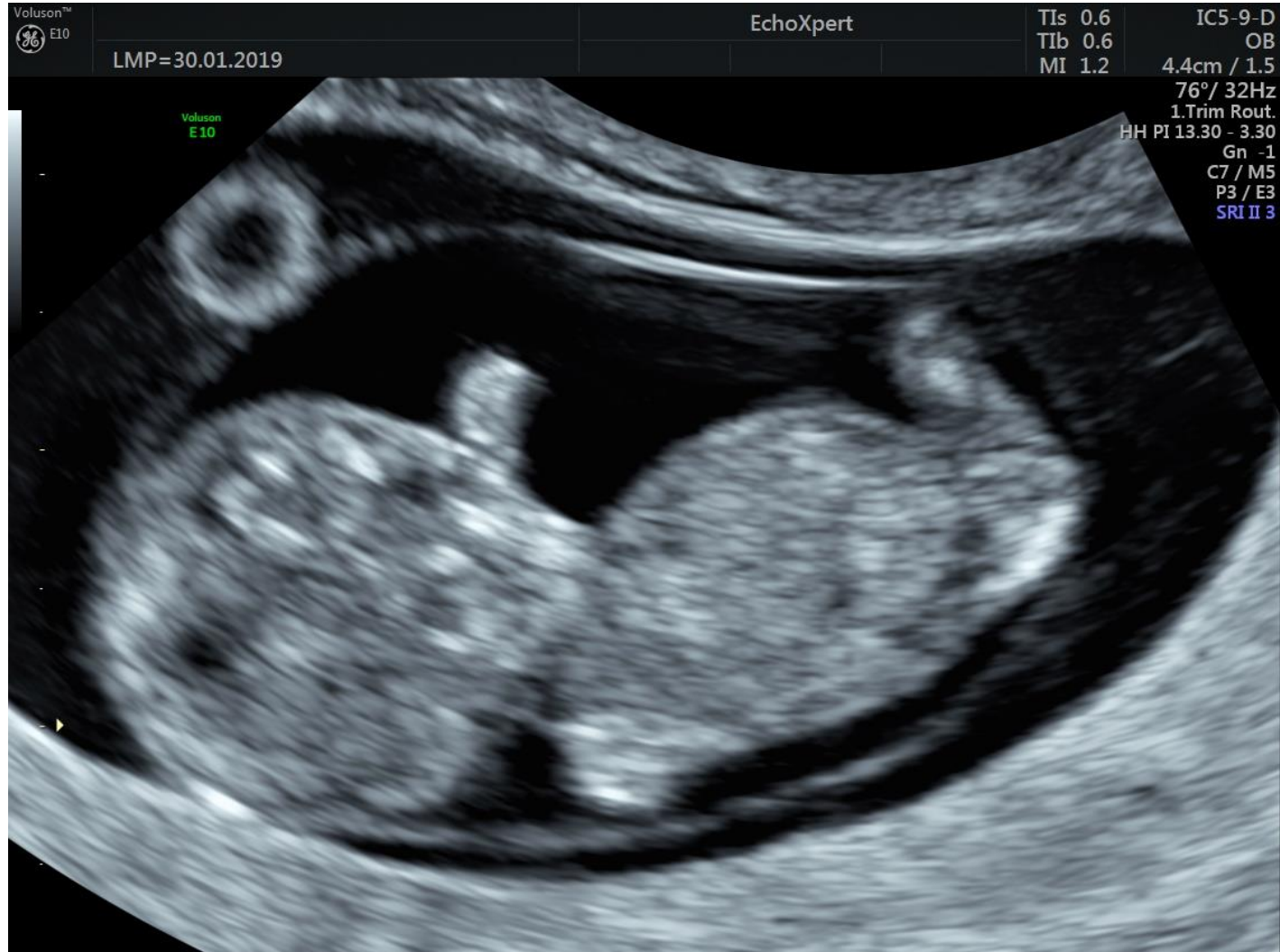Foto 32a/b



# Dooierzak / vruchtzak

Dooierzak en amnionvlies 10+ wk (TV/TA)

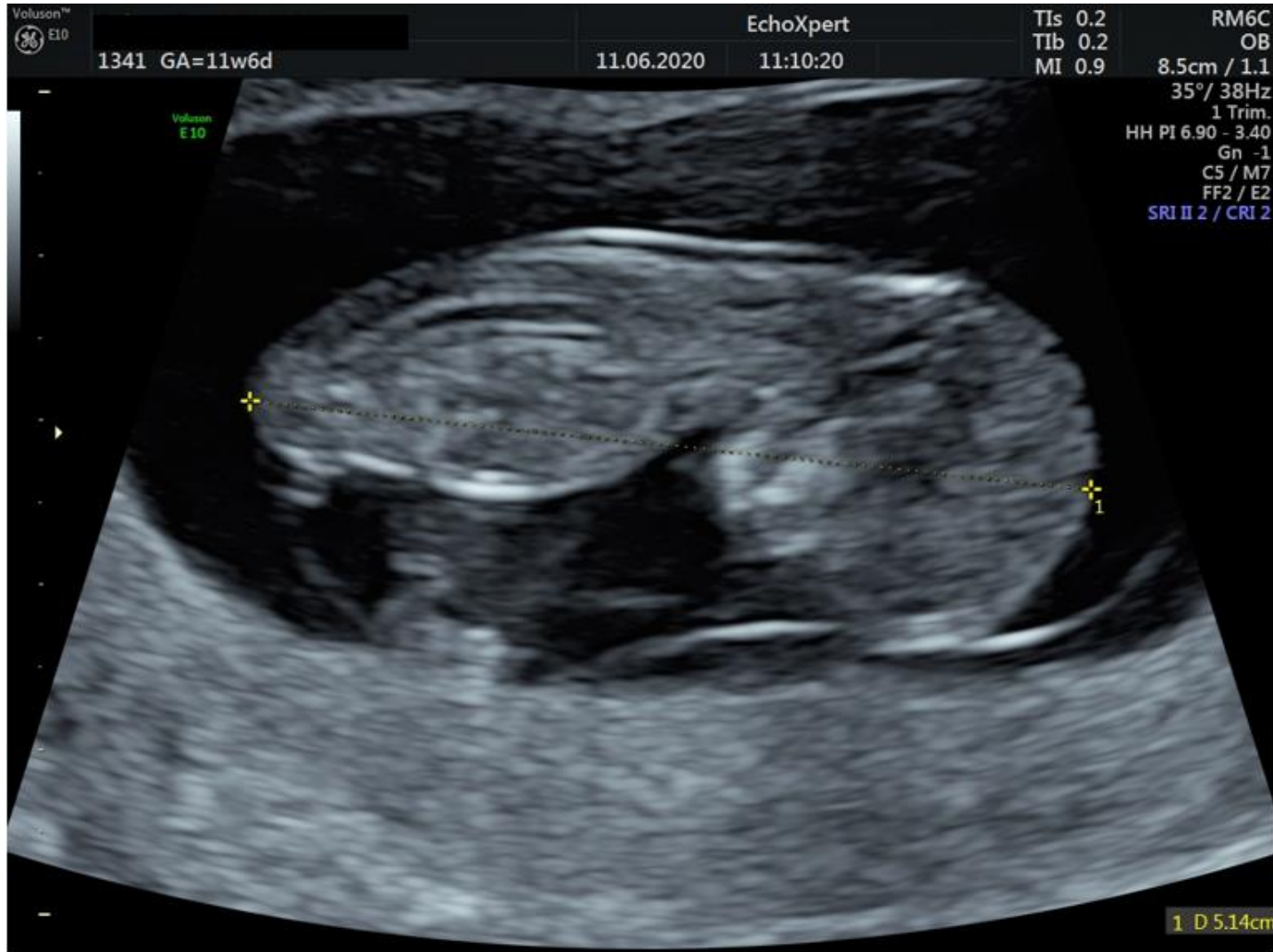Foto 33a/b



# Dooierzak / vruchtzak

Dooierzak en amnionvlies 11+ wk (TV/TA)

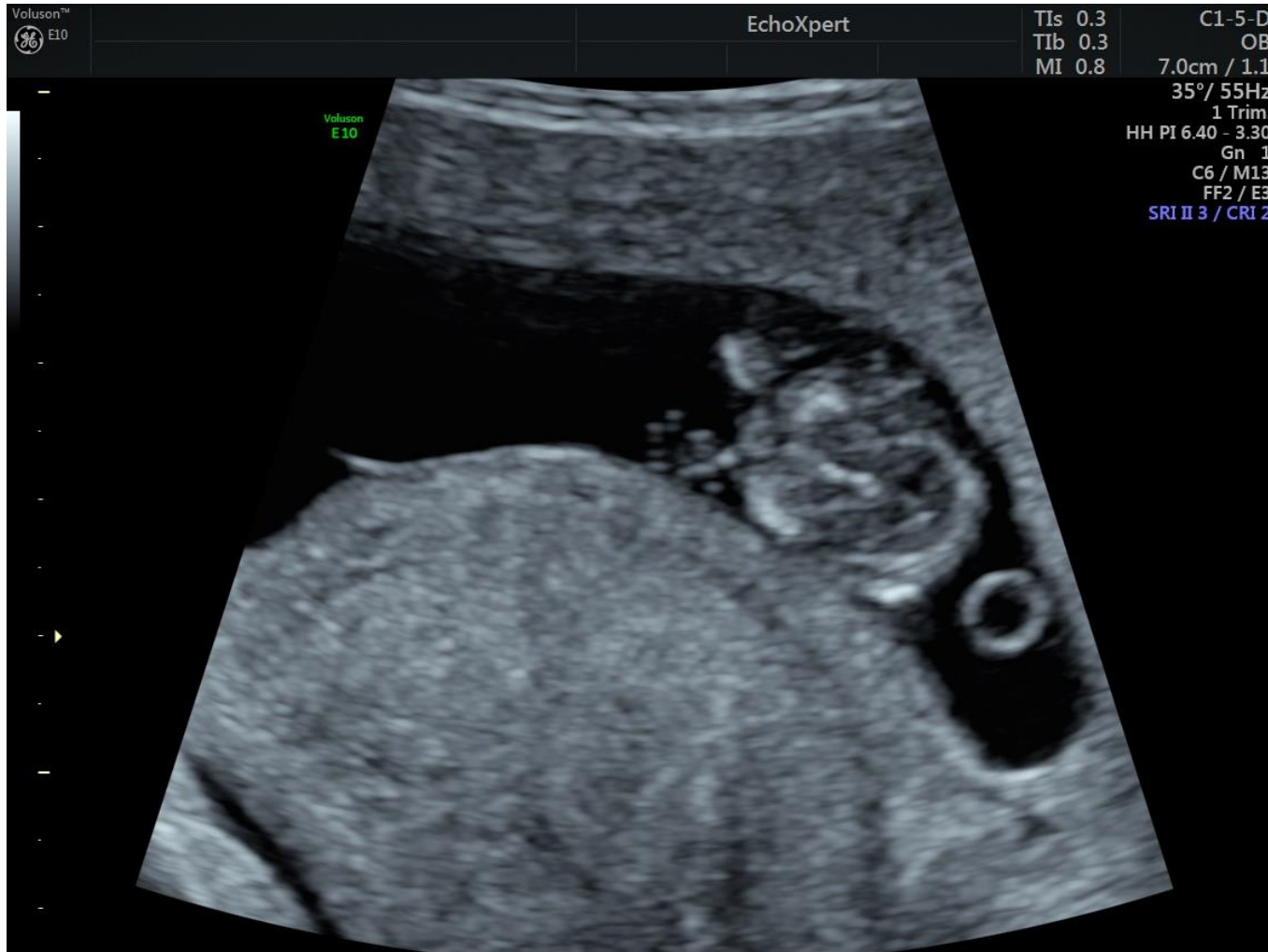Foto 34a



# Dooierzak / vruchtzak

Dooierzak en amnionvlies 11+ wk (TV/TA)

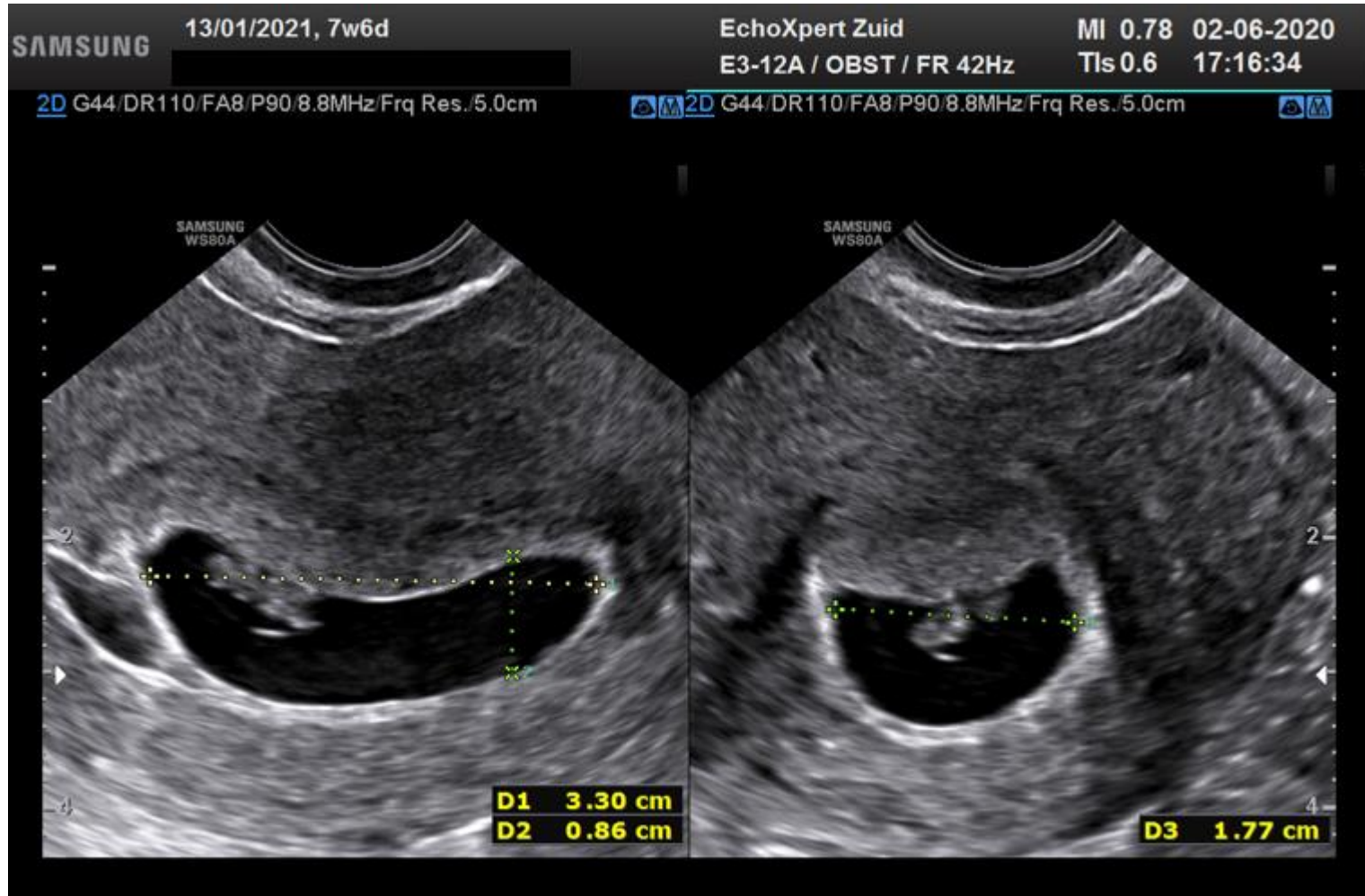
Foto 34b



# Vruchtzakmeting

Vruchtzakmeting in 3 richtingen < 8 weken

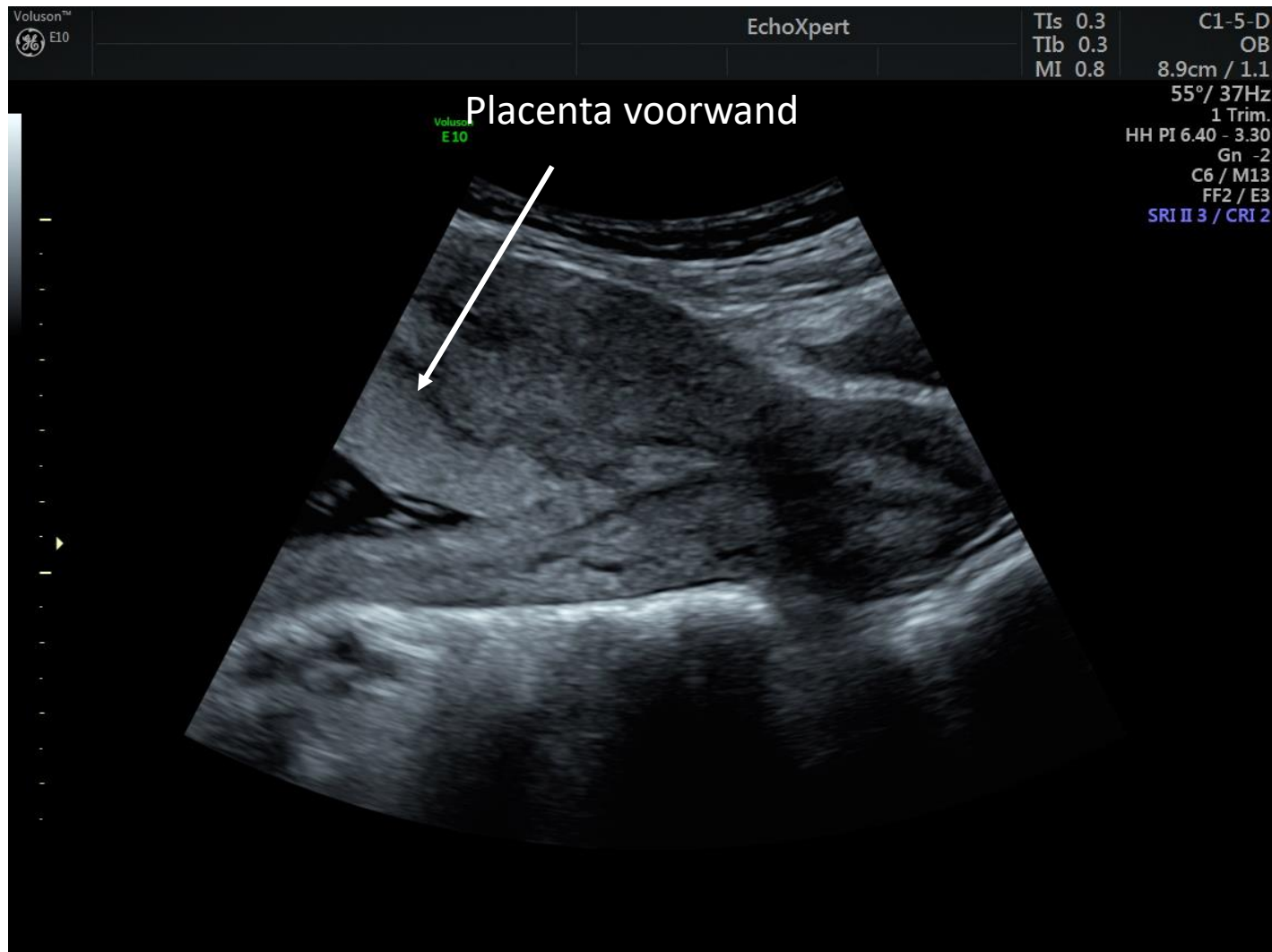
Foto 35a/b



# Overige structuren

Placentalokalisatie in sagittaal vlak (TA)

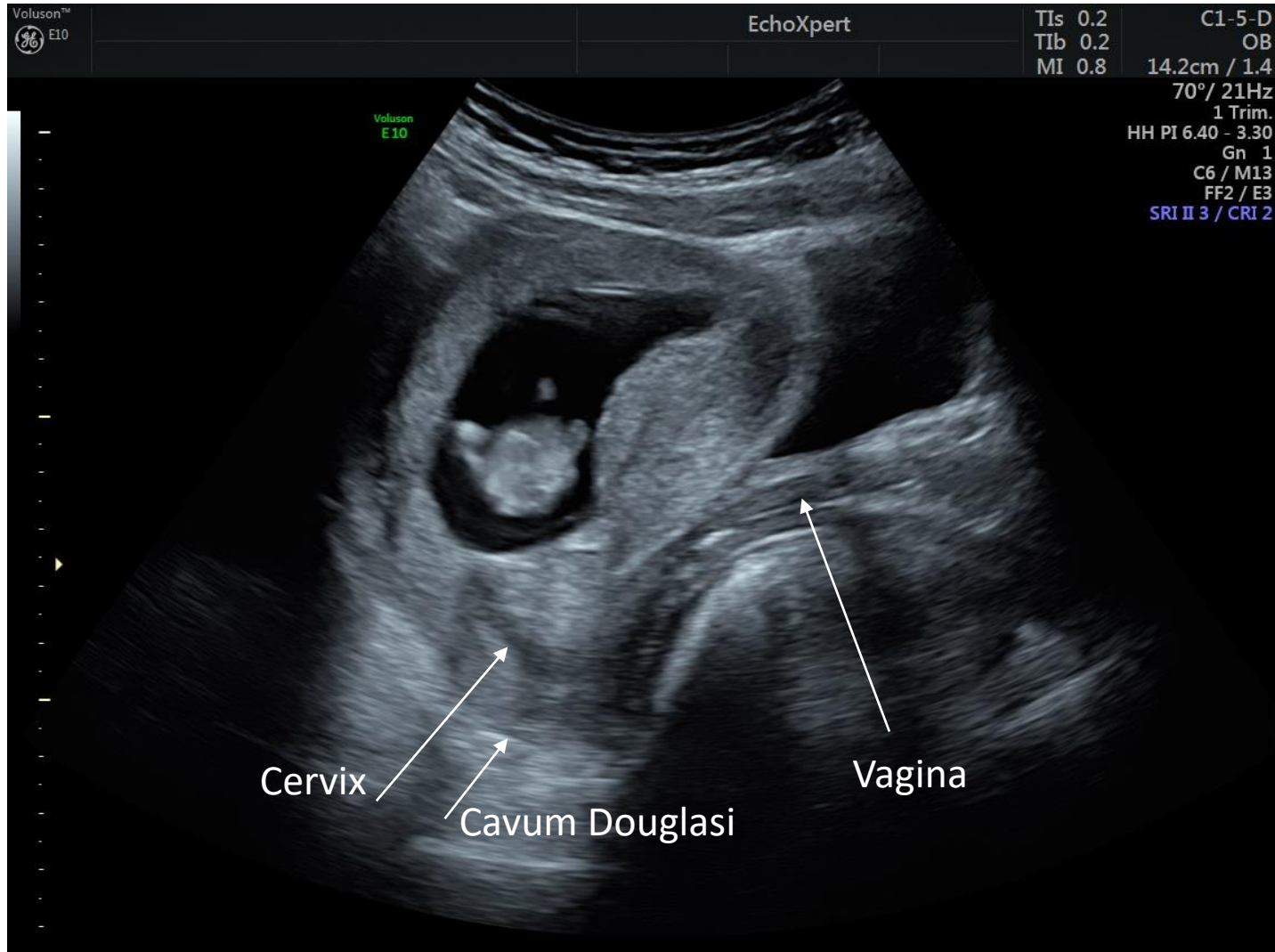
Foto 36/37



# Overige structuren

Cervix, vagina en cavum Douglasi (dorsaal van de blaas) (TA)

Foto 38/39

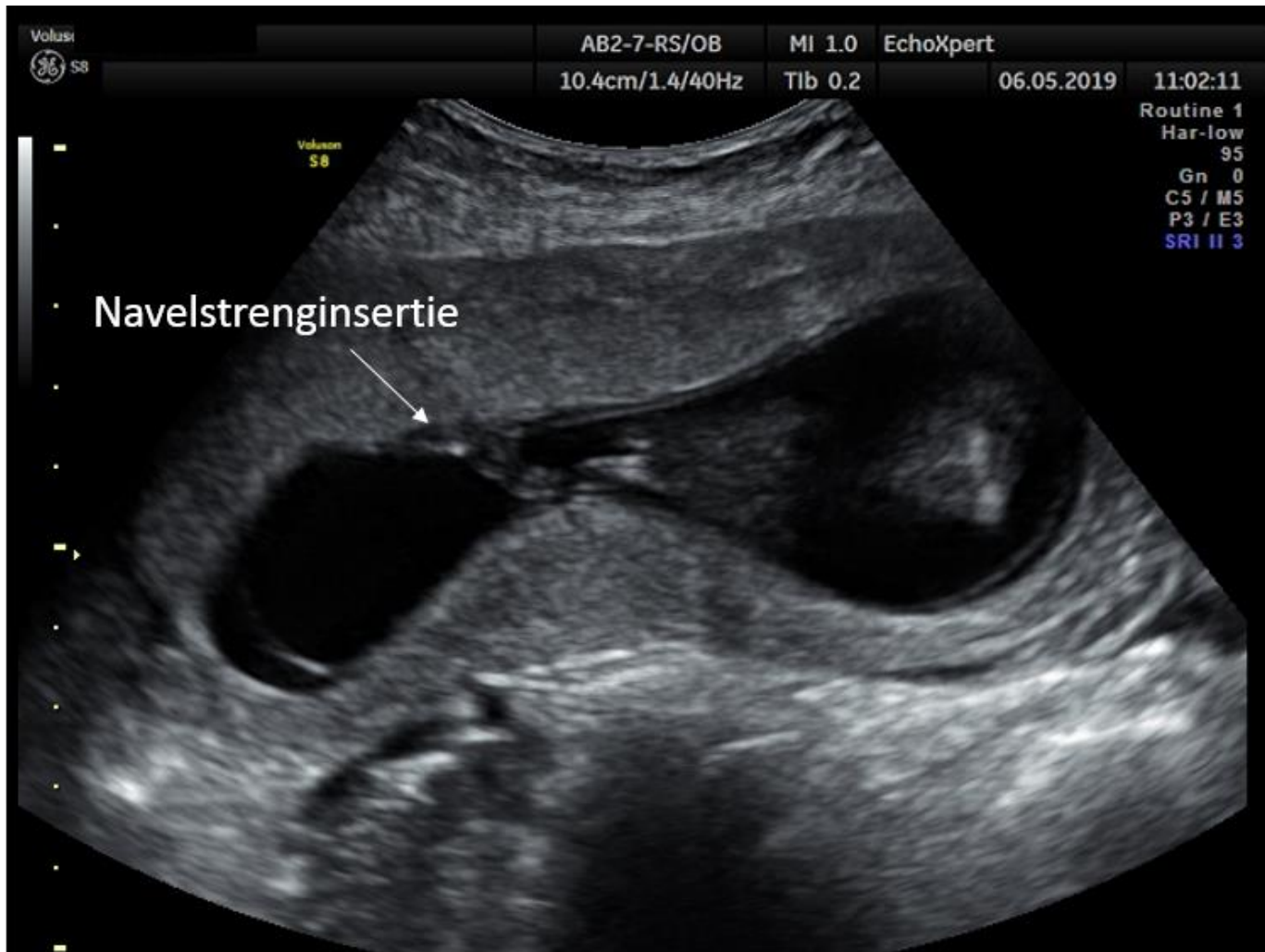




# Overige structuren

Navelstrenginsertie in placenta (TA)

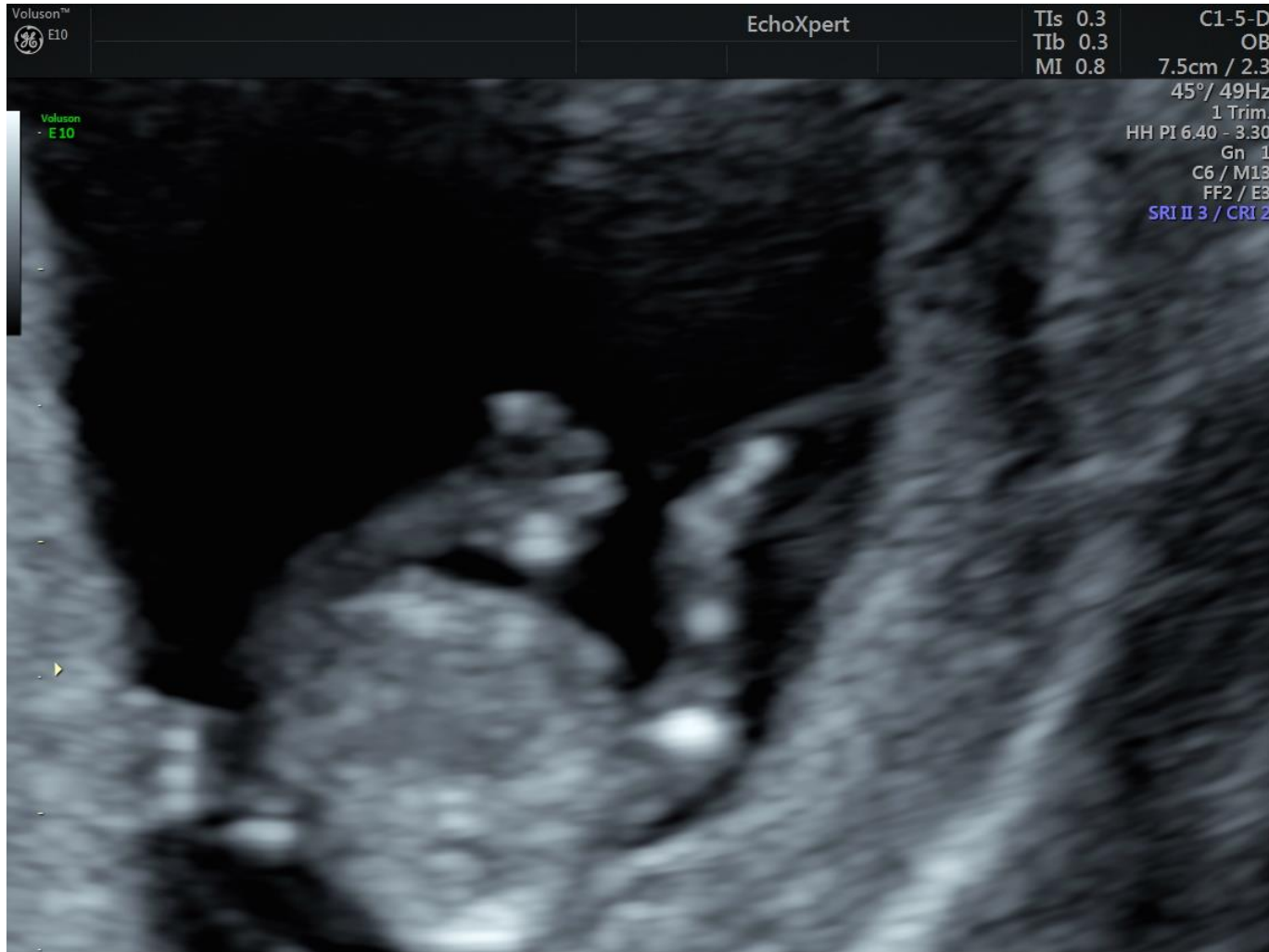Foto 40/41



# Foetale structuren

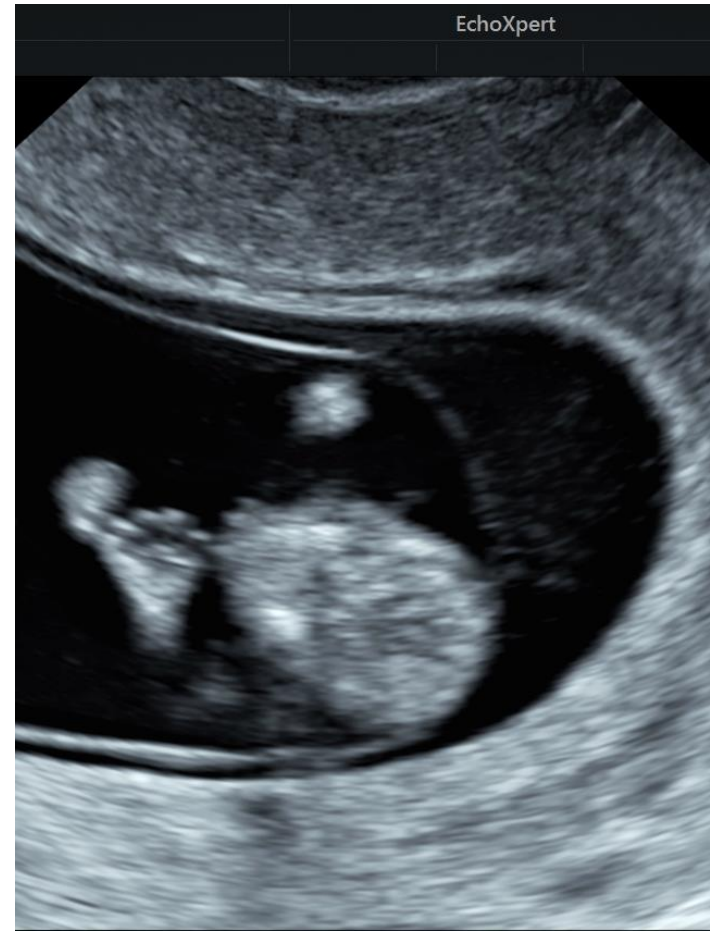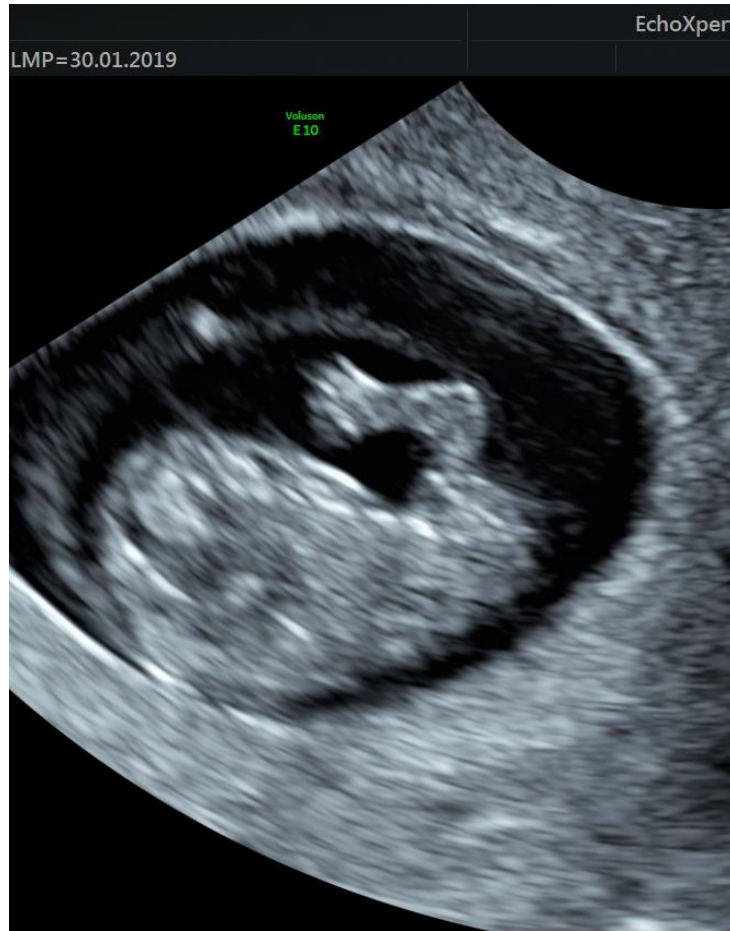10+ wk armen (TV/TA)

Foto 42 (mag in 2 foto's, a/b)



# Foetale structuren

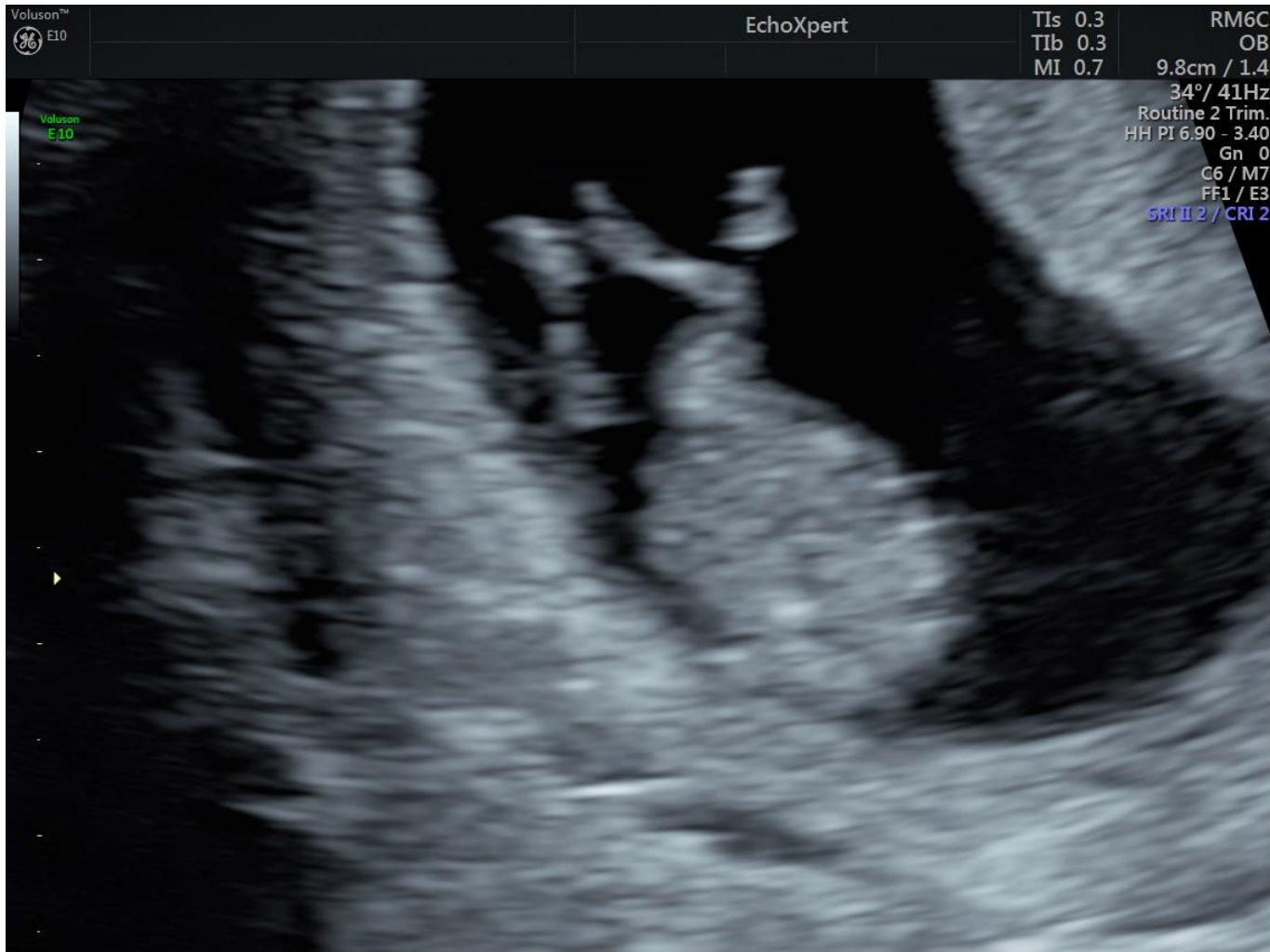
10+ wk armen (TV/TA)  
voorbeeld van foto 42 in 2 foto's



# Foetale structuren

10+ wk benen (TV/TA)

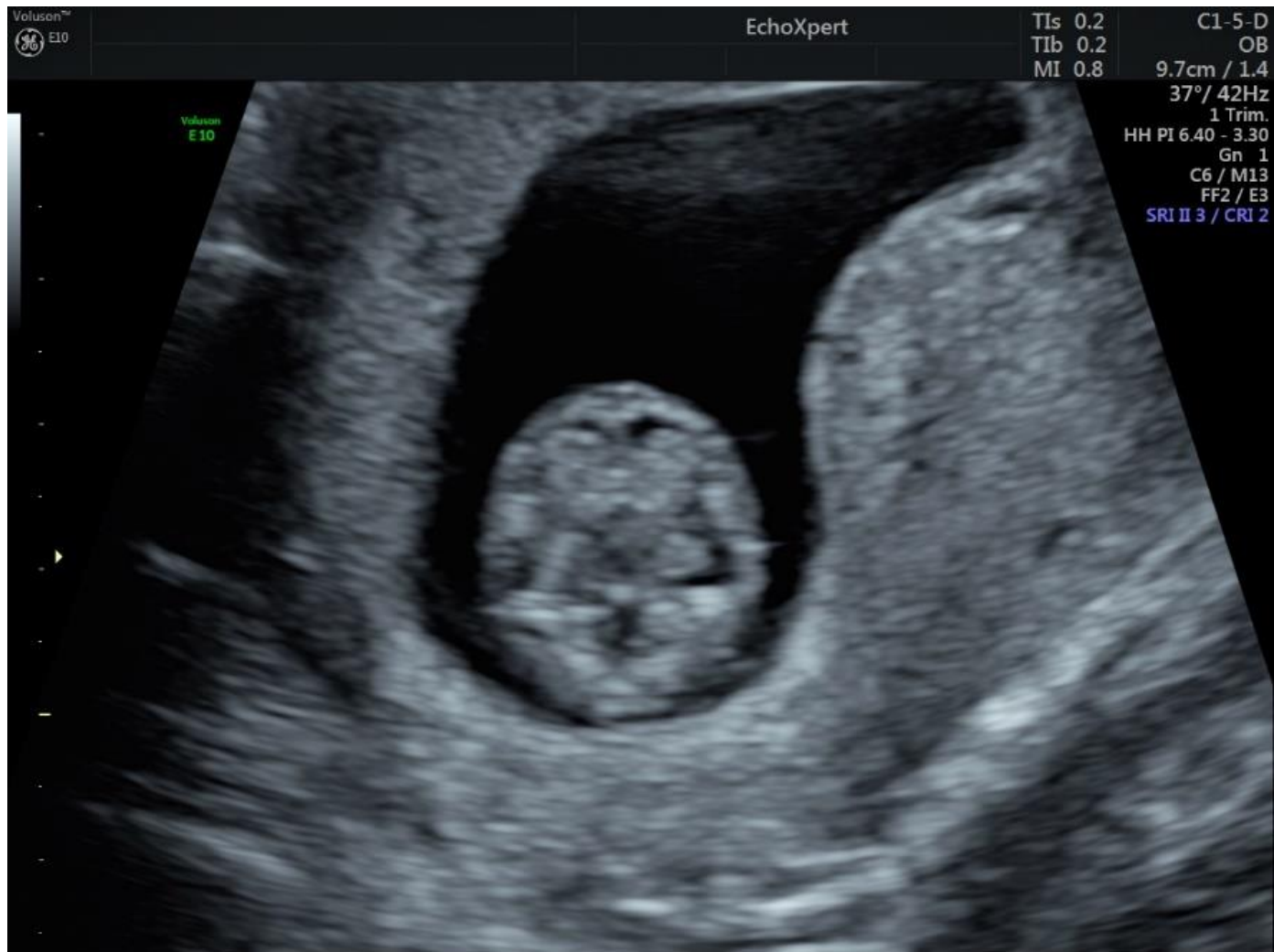Foto 43



# Foetale structuren

11+ wk HC midline

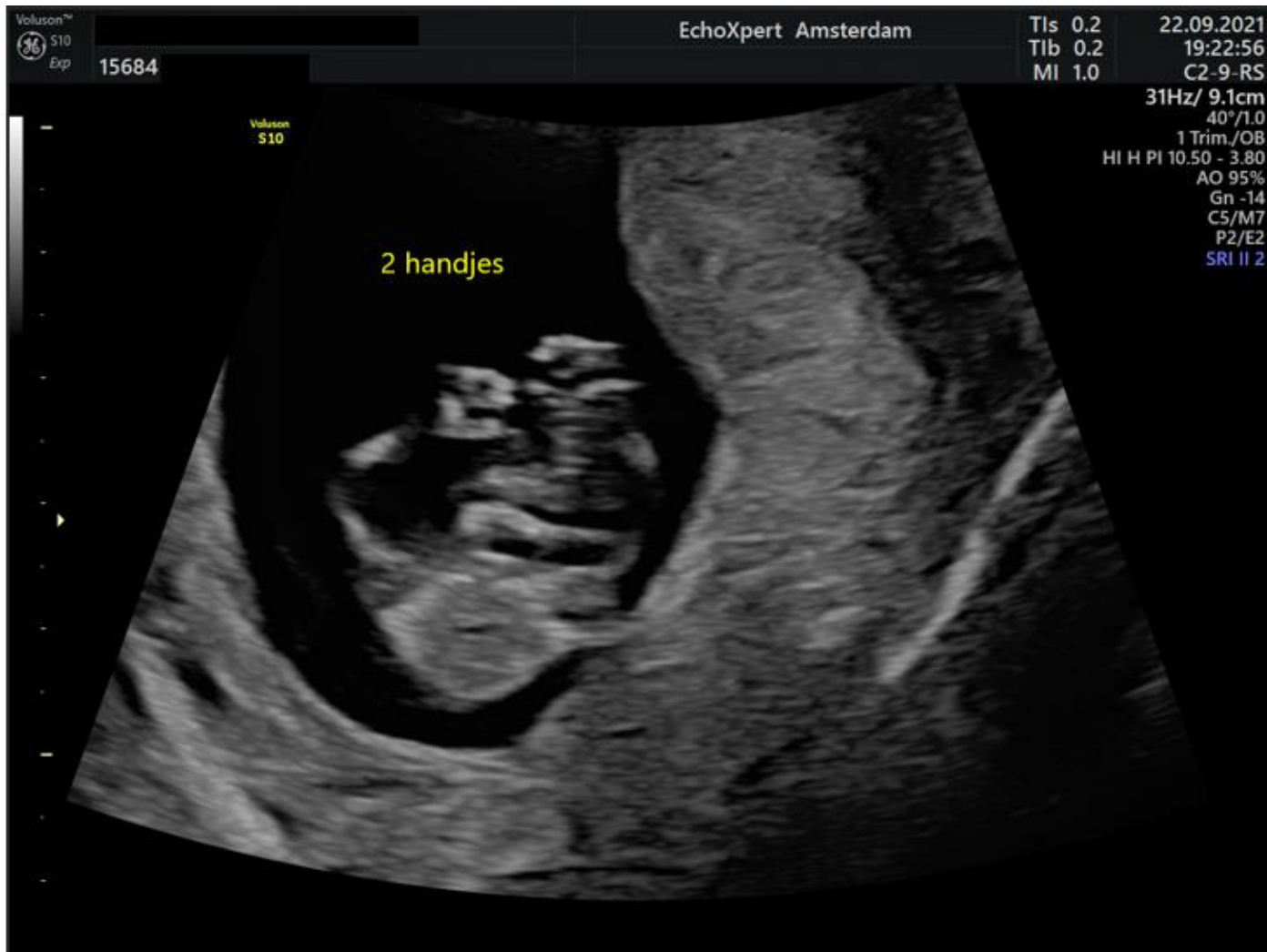Foto 44



# Foetale structuren

11+ wk armen

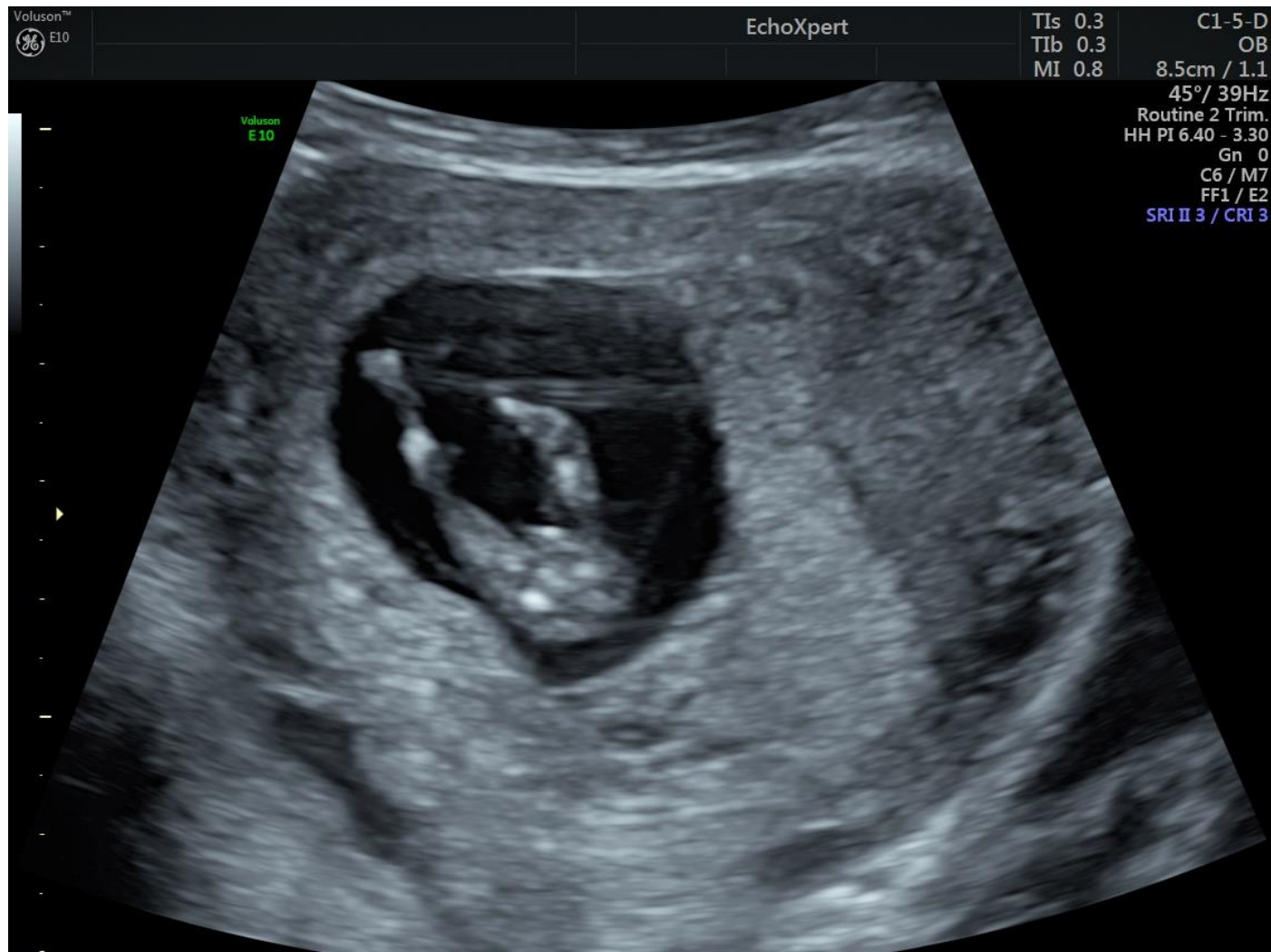Foto 45 (mag in 2 foto's)



# Foetale structuren

11+ wk benen

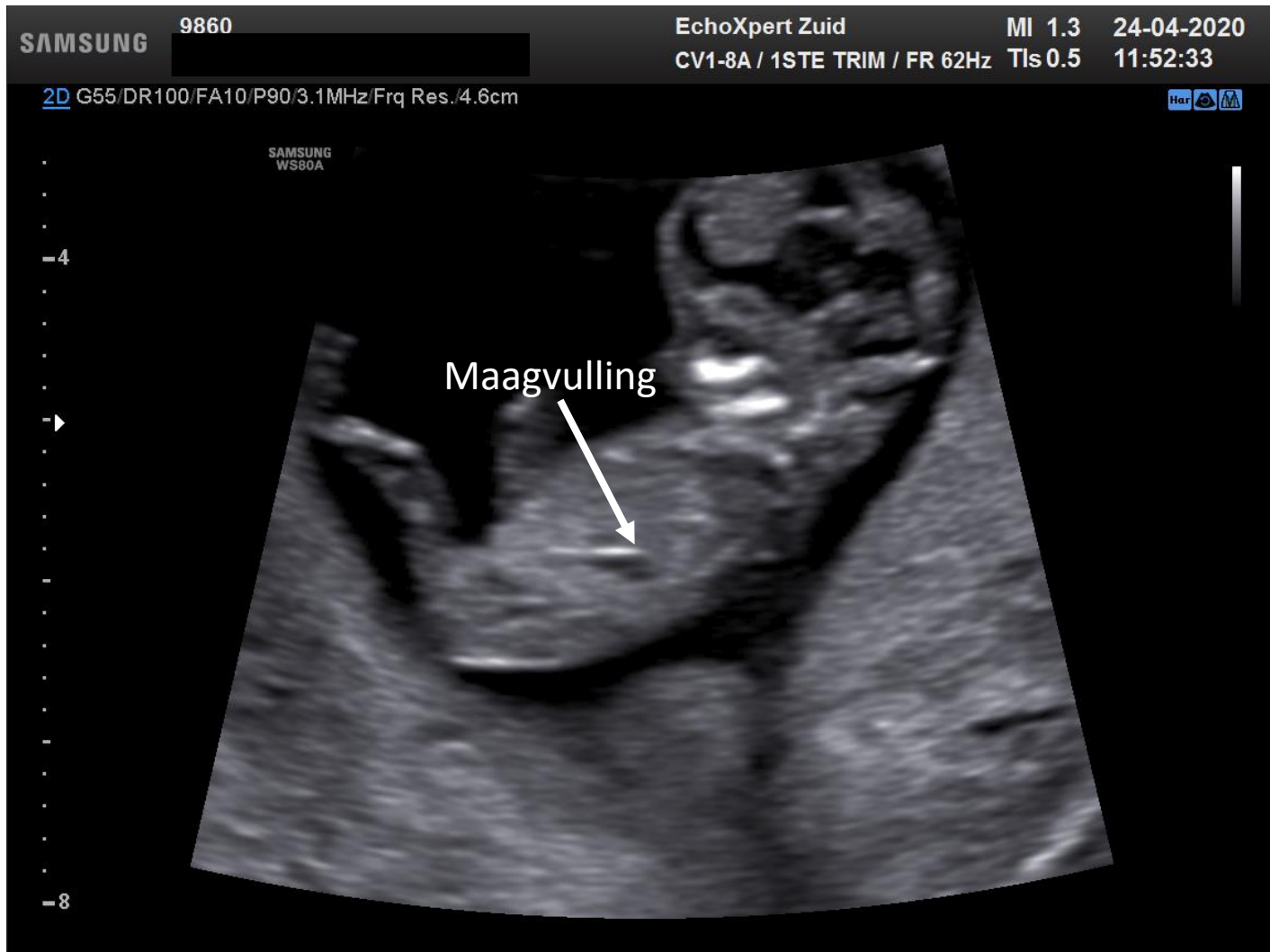Foto 46



# Foetale structuren

11+ wk maagvulling

Foto 47 (vb sagittaal)

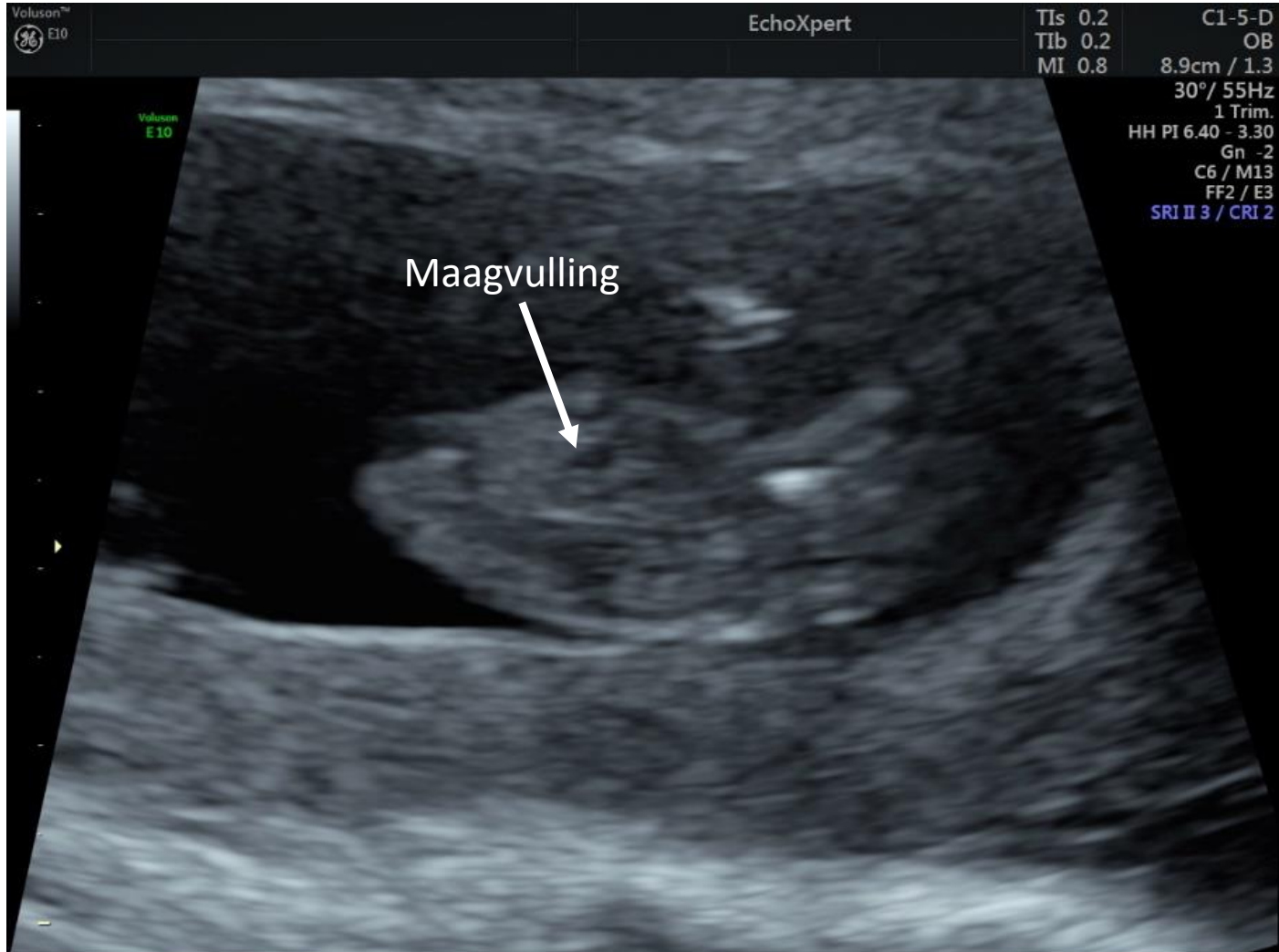



# Foetale structuren

11+ wk maagvulling

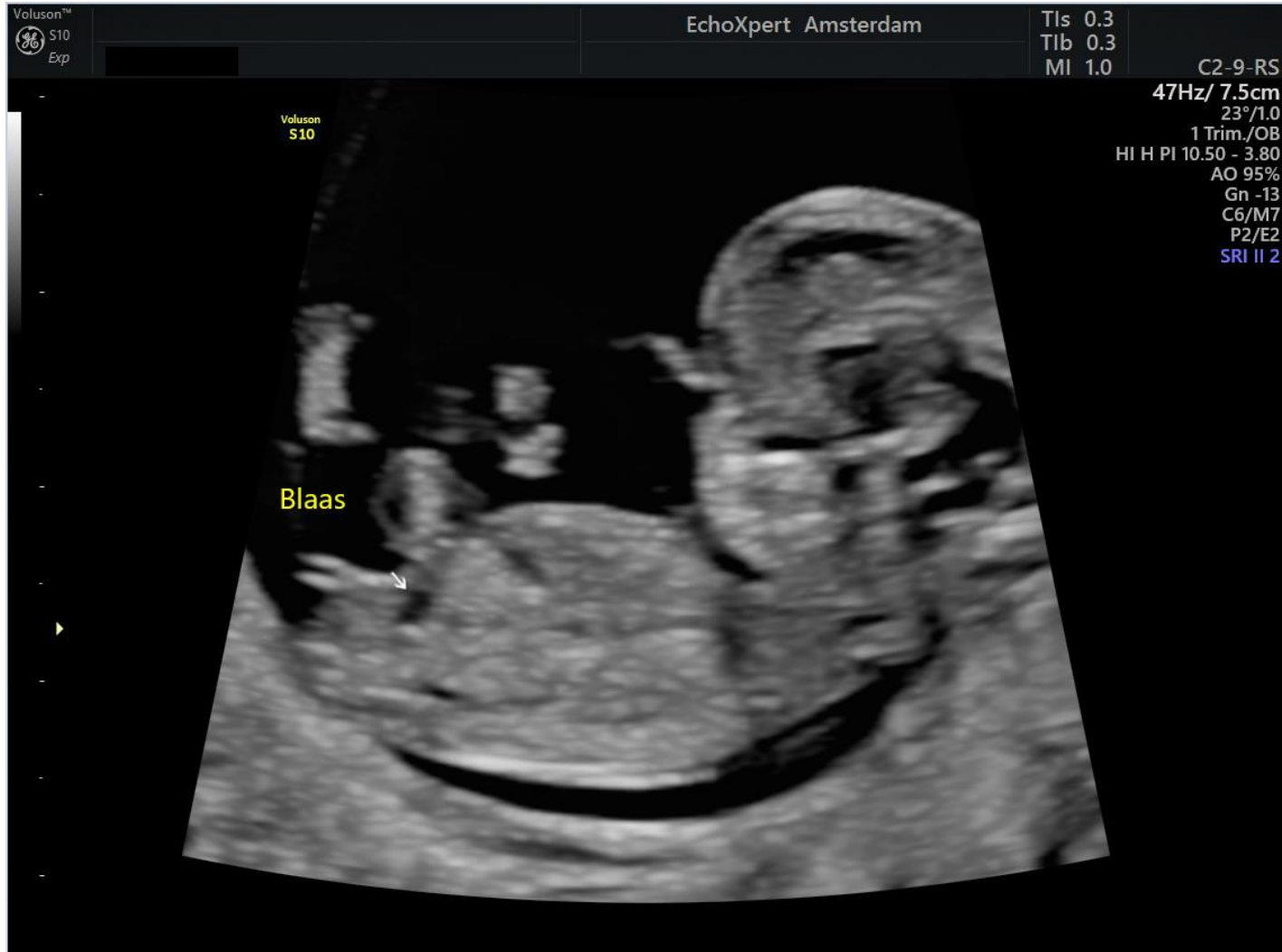Foto 47 (vb coronaal)



# Foetale structuren

11+ wk blaasvulling

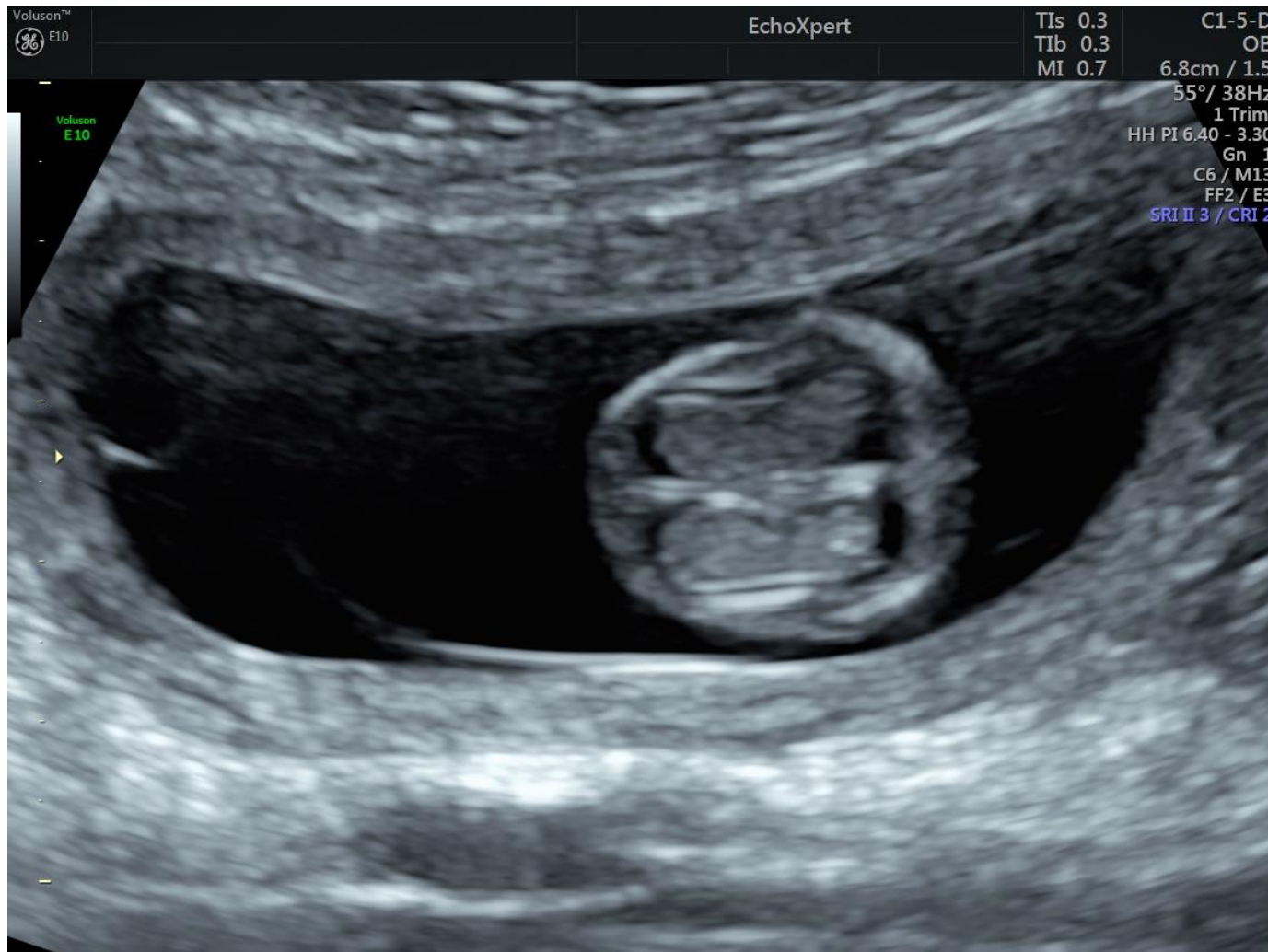
Foto 48



# Foetale structuren

12+ wk HC midline

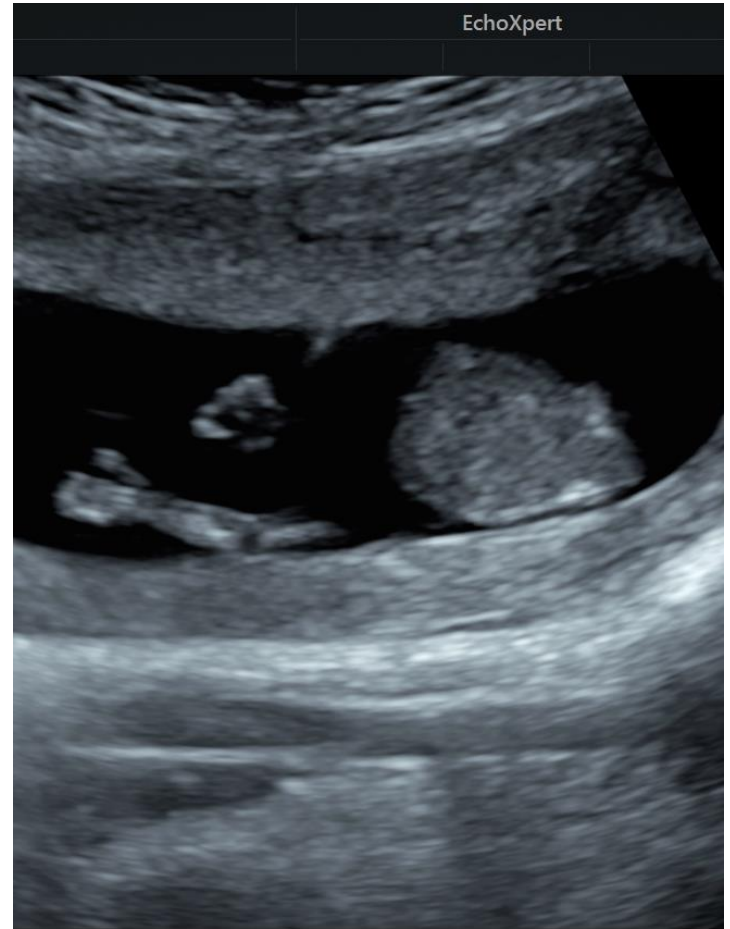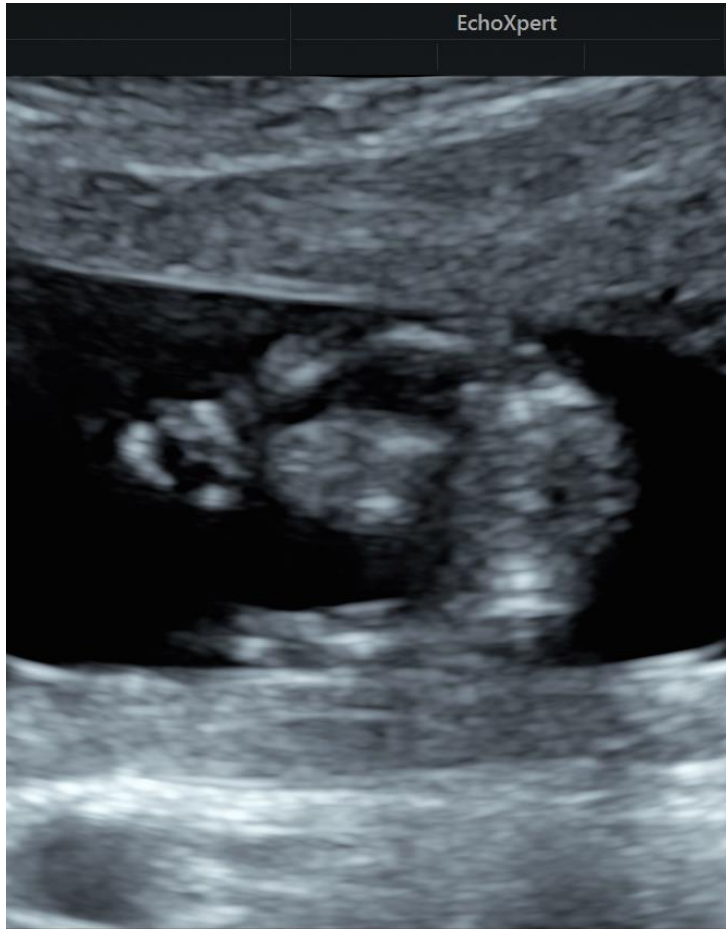Foto 49



# Foetale structuren

12+ wk armen

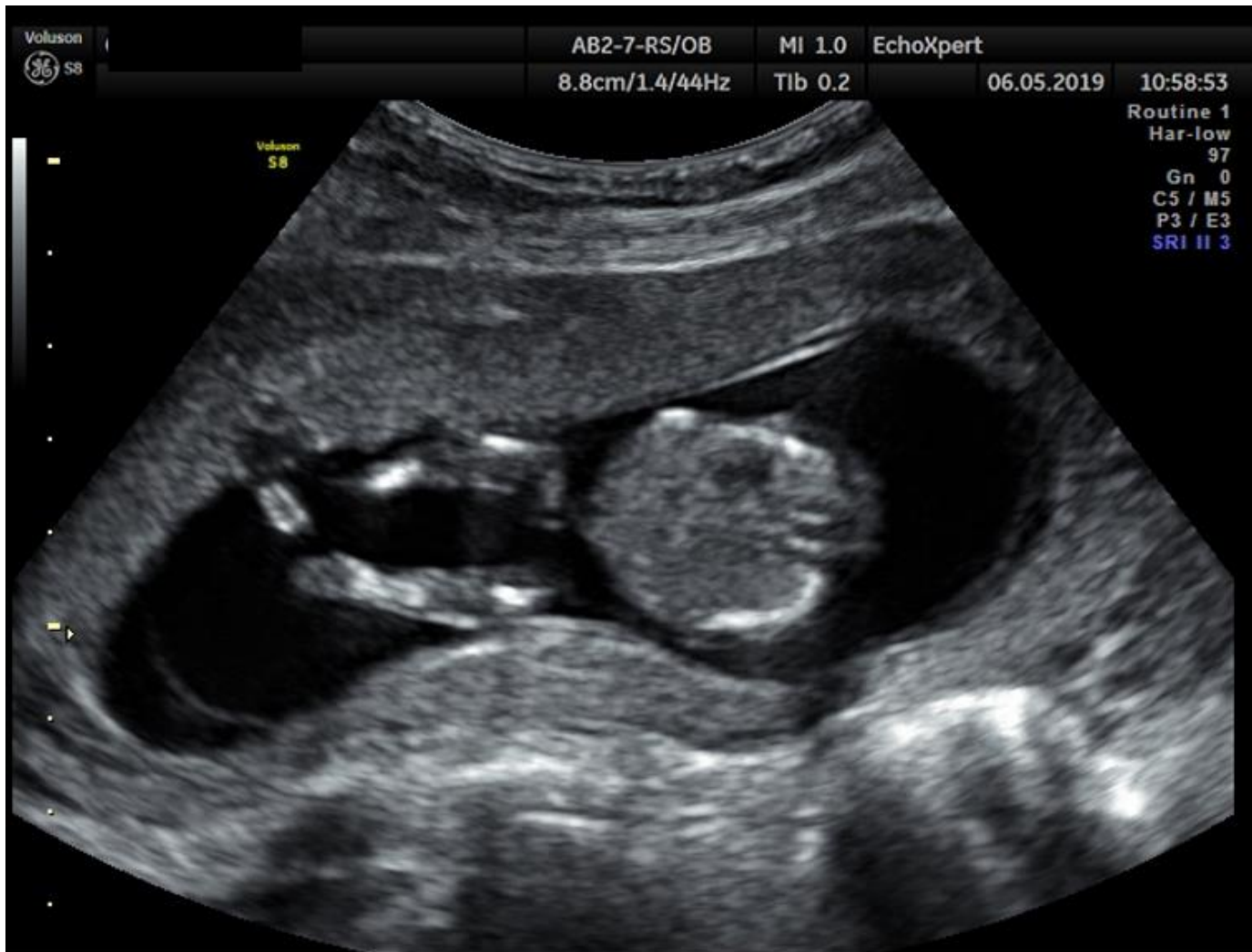Foto 50



# Foetale structuren

12+ wk benen

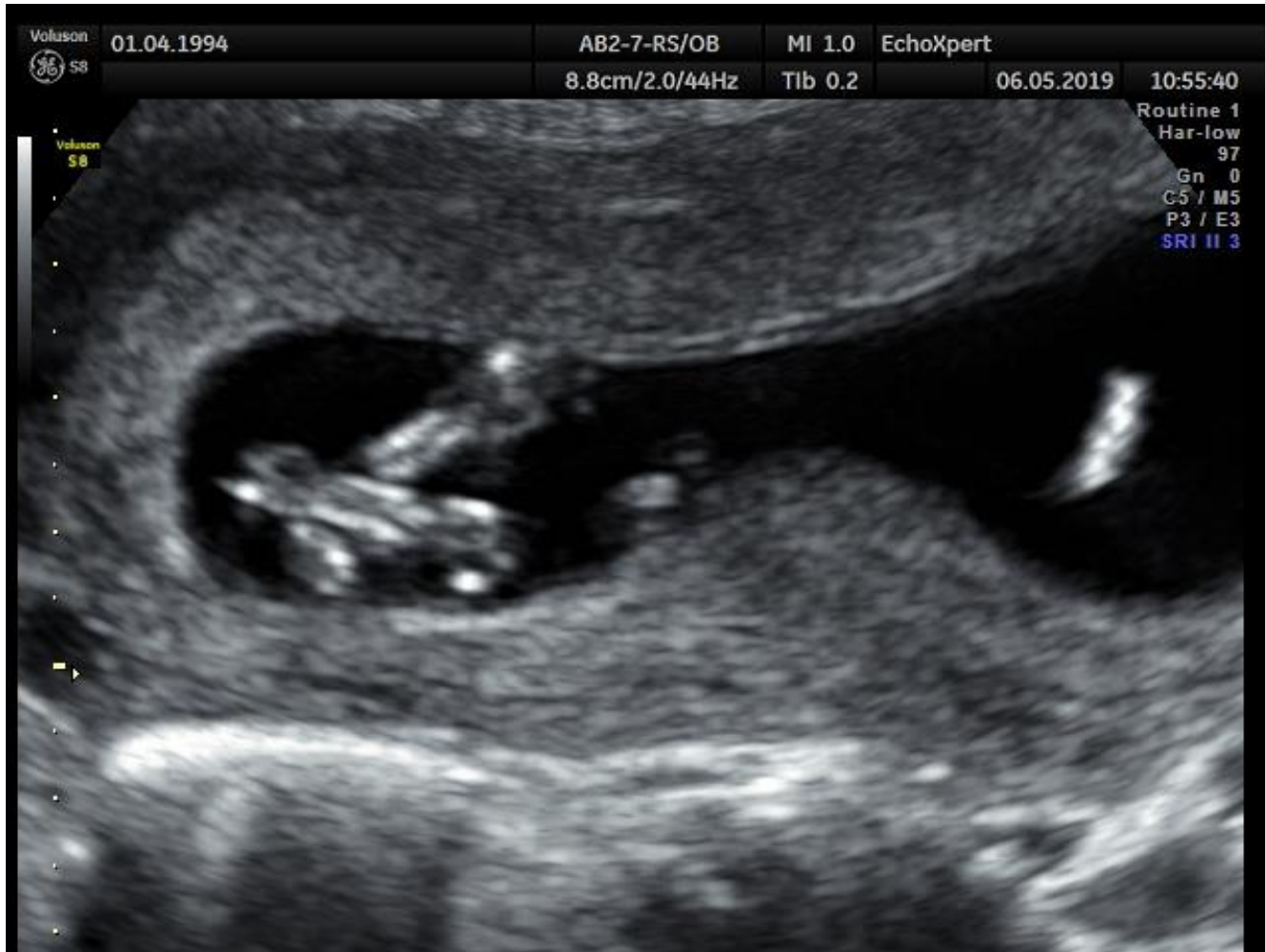Foto 51



# Foetale structuren

12+ wk benen (voorbeeld gekruist)

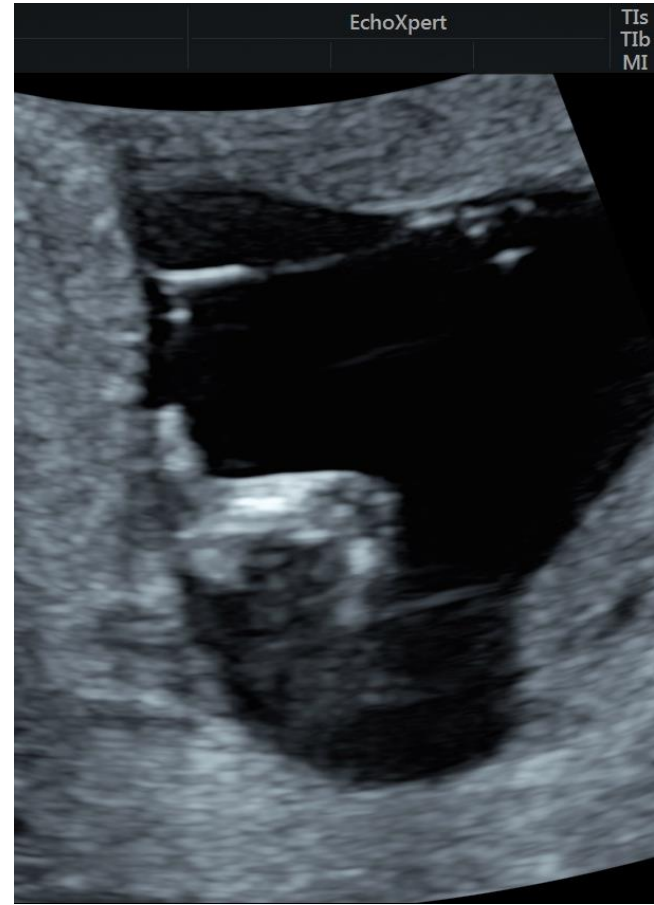
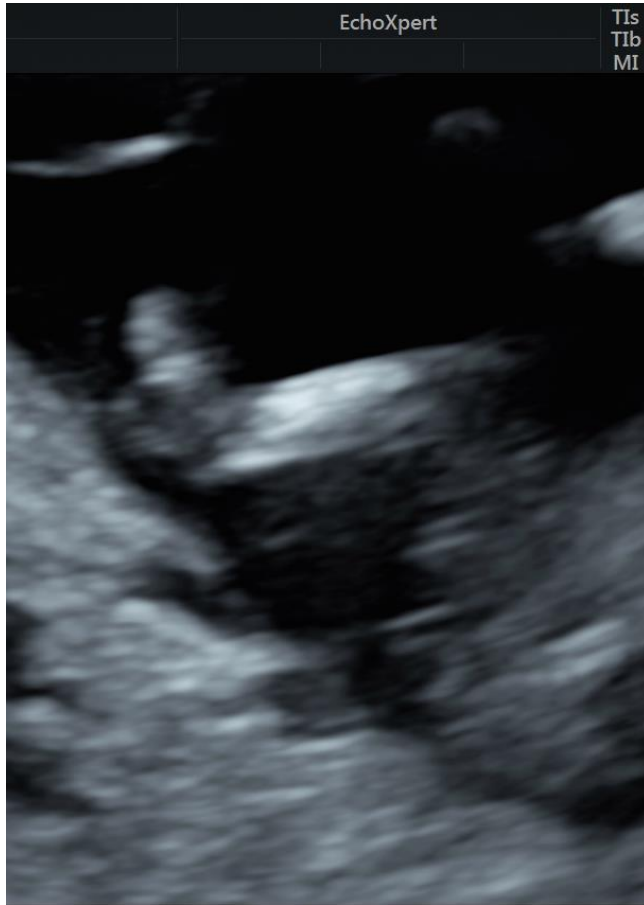Foto 51



# Foetale structuren

12+ wk benen (voorbeeld los van elkaar)

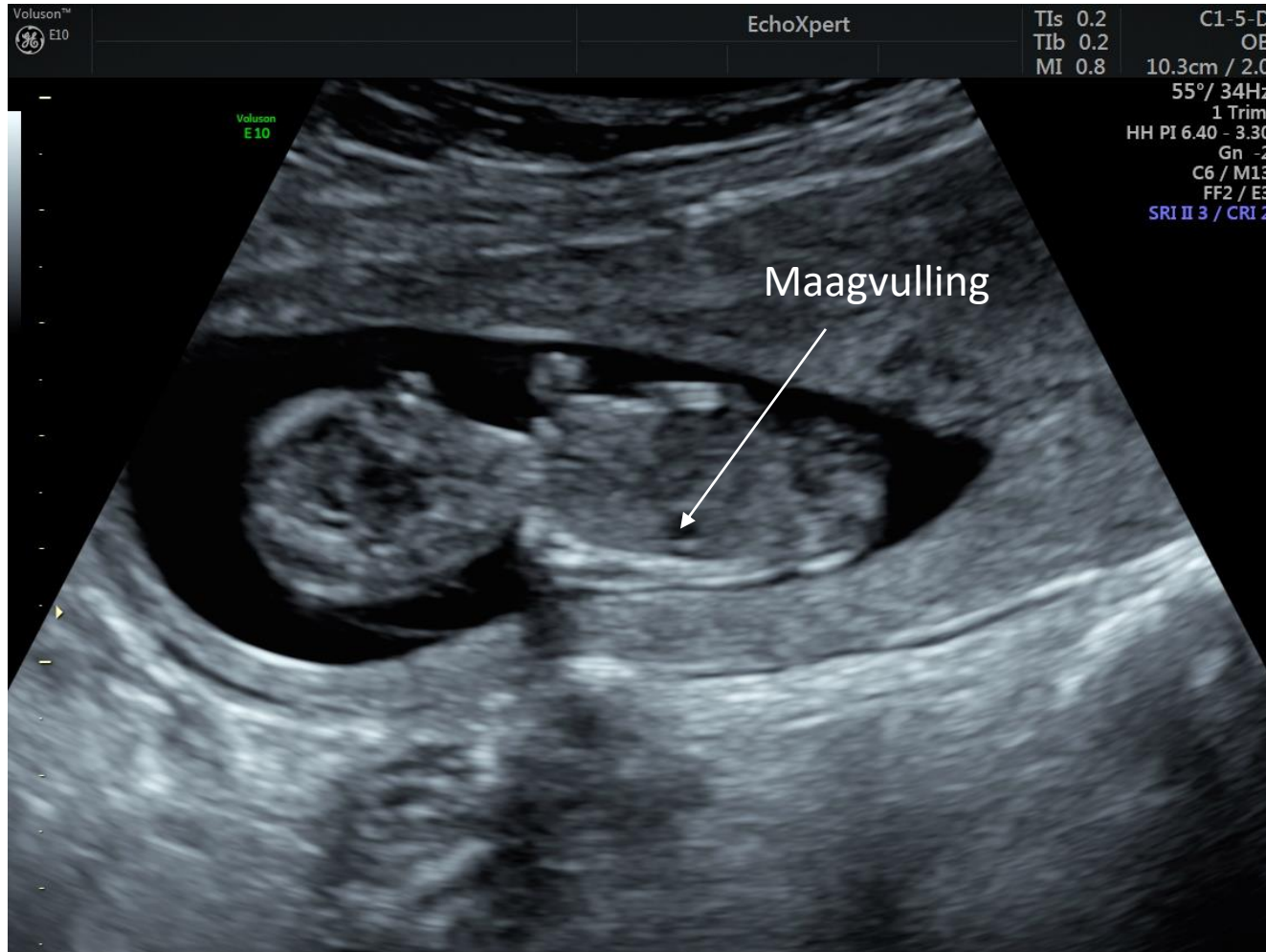
Foto 51



# Foetale structuren

12+ wk maagvulling

Foto 52

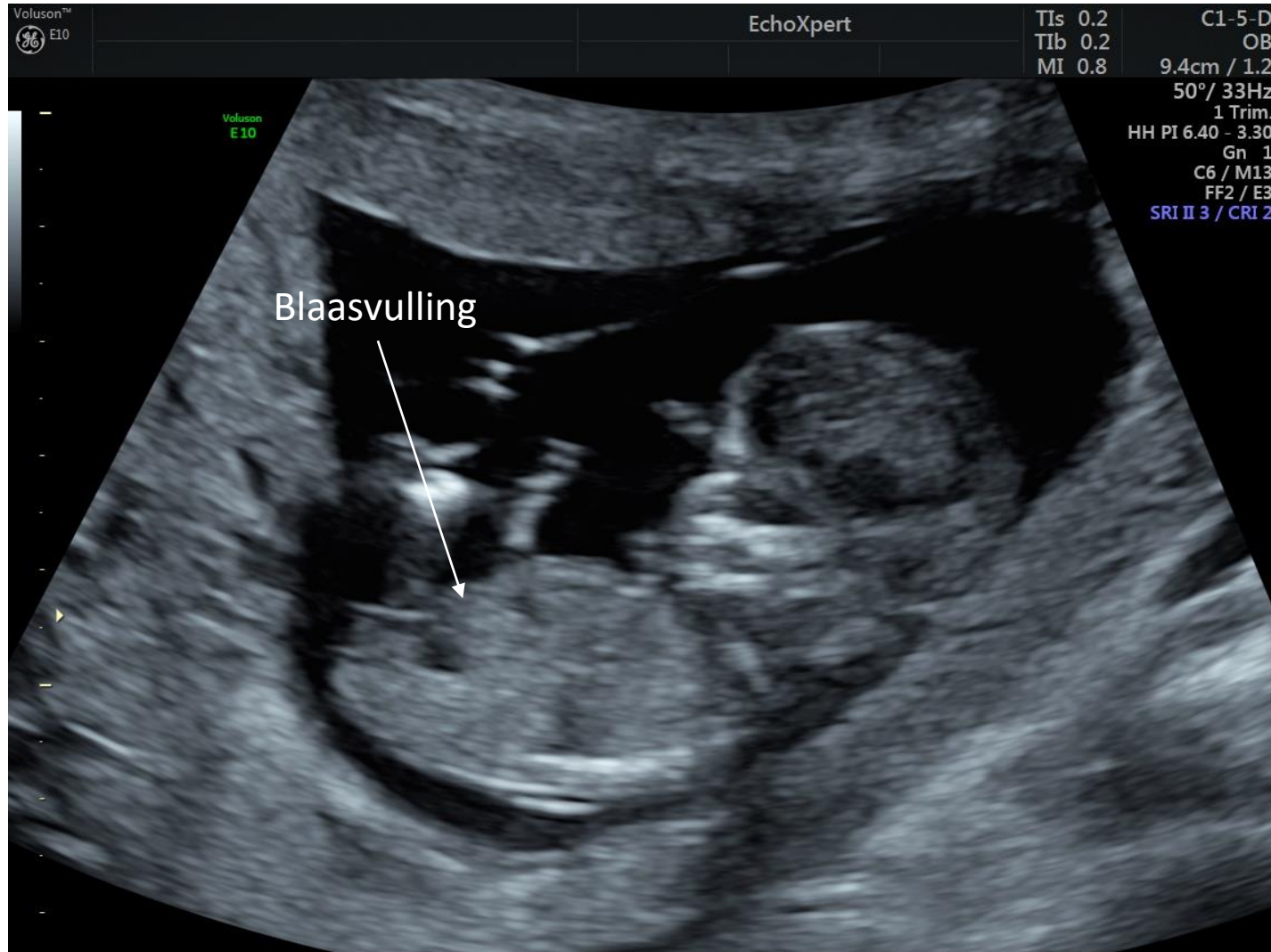



# Foetale structuren

12+ wk blaasvulling

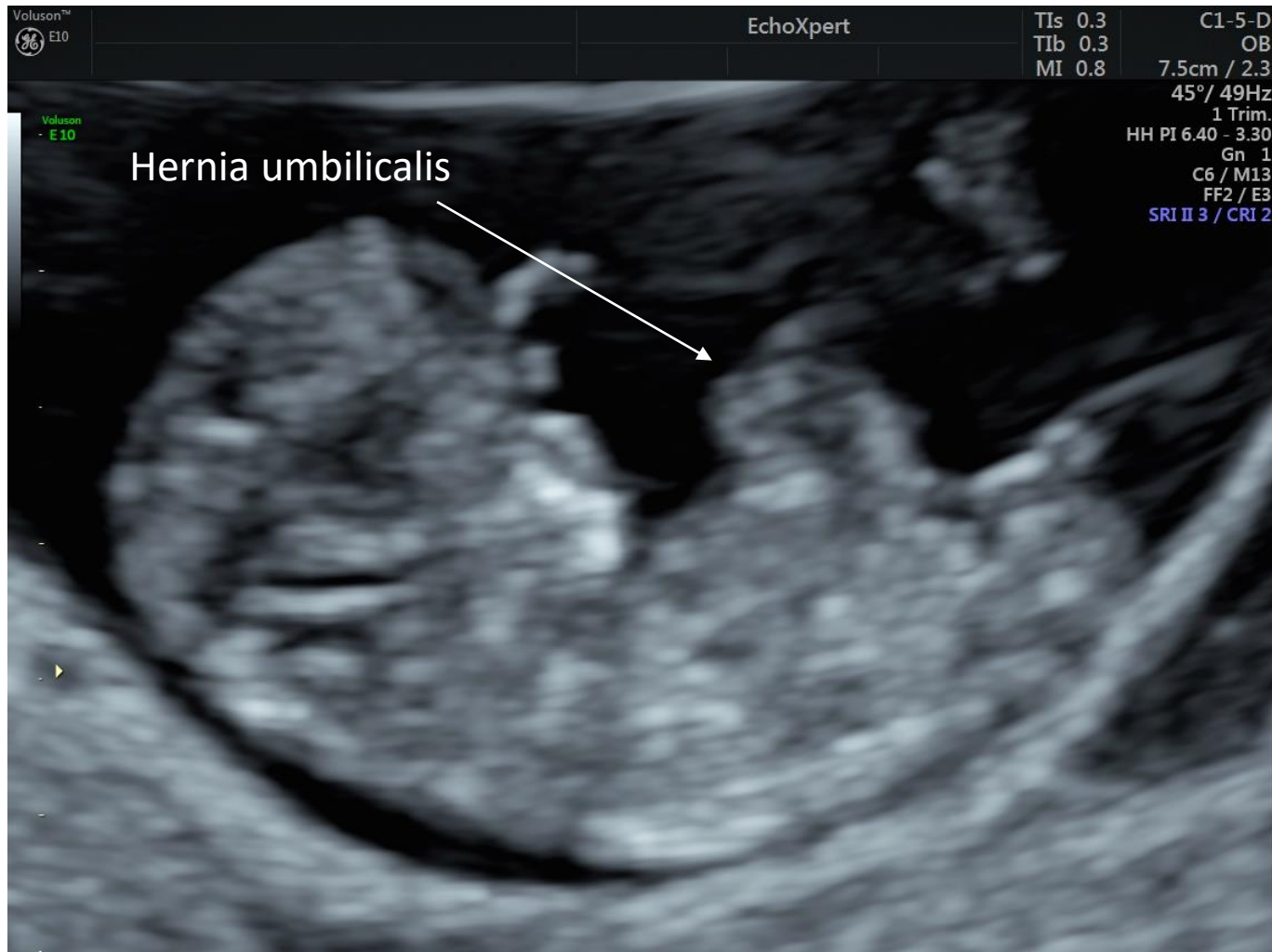Foto 53



# Foetale structuren

Fysiologische hernia umbilicalis bij 9-11 wk (TV/TA)

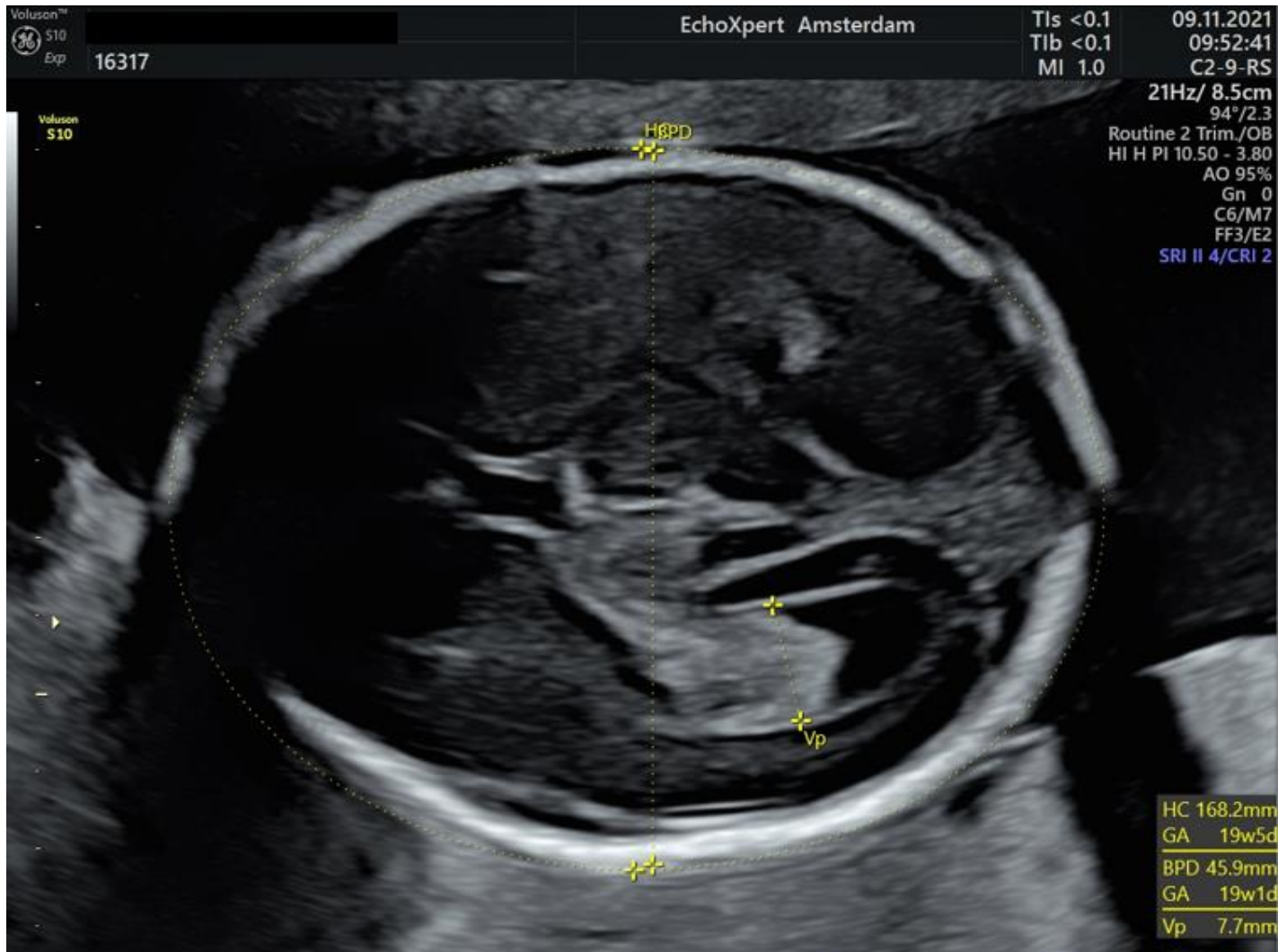
Foto 54/55



# 2<sup>e</sup> - 3<sup>e</sup> trimester biometrie

18-24 wk HC/DBP

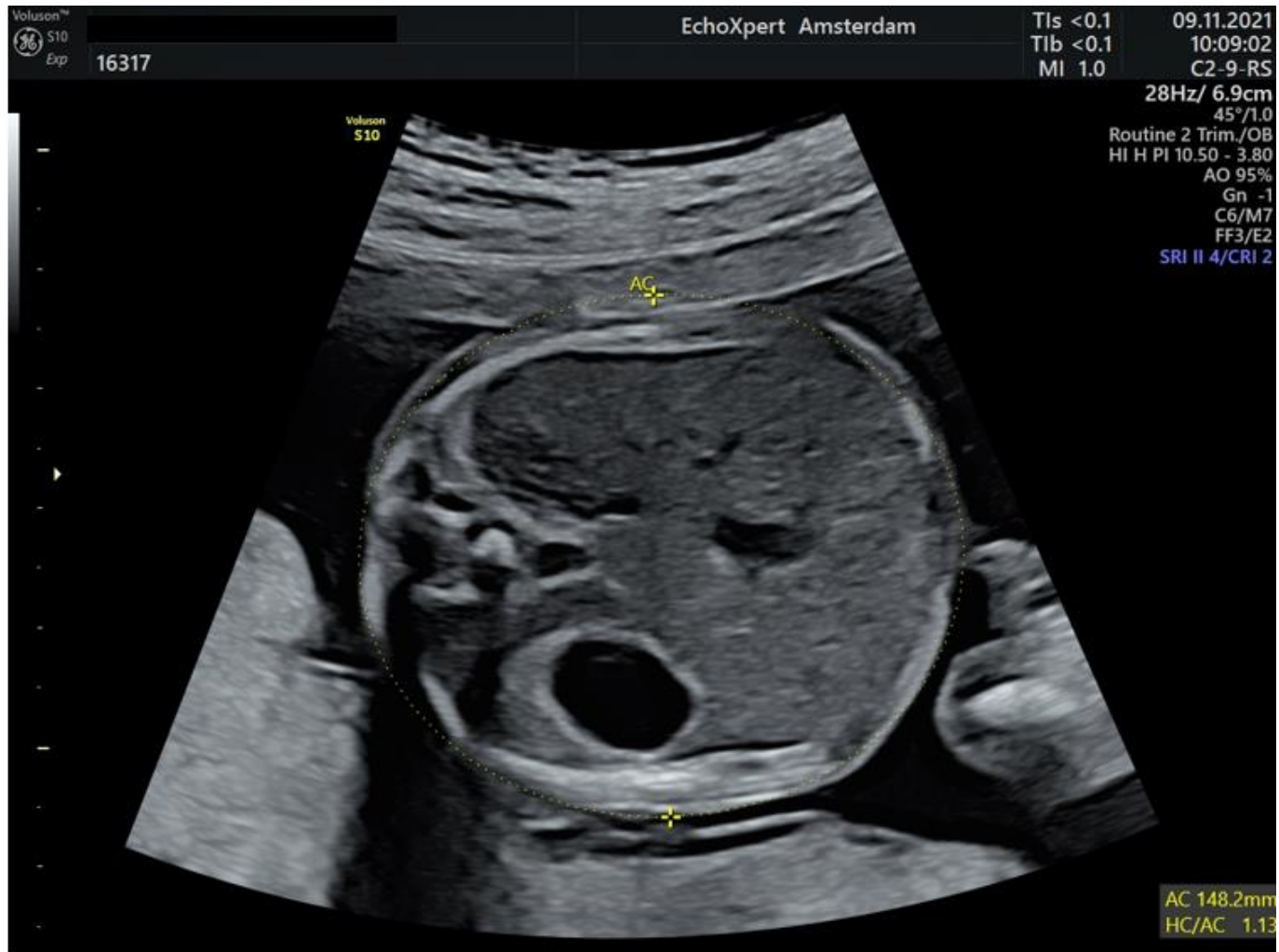Foto 56/59/62



# Biometrie

18-24 wk AC

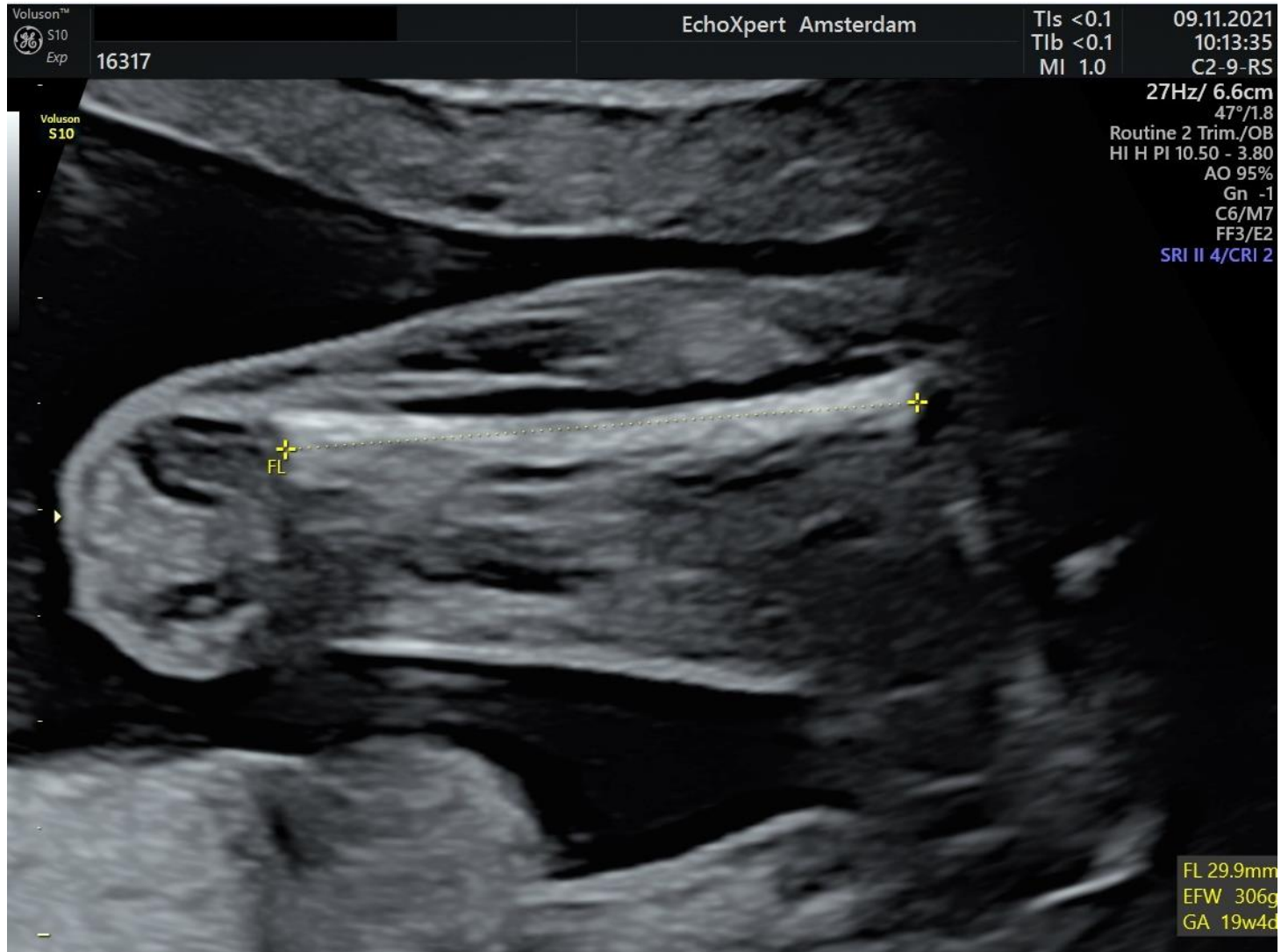Foto 57/60/63



# Biometrie

18-24 wk FL

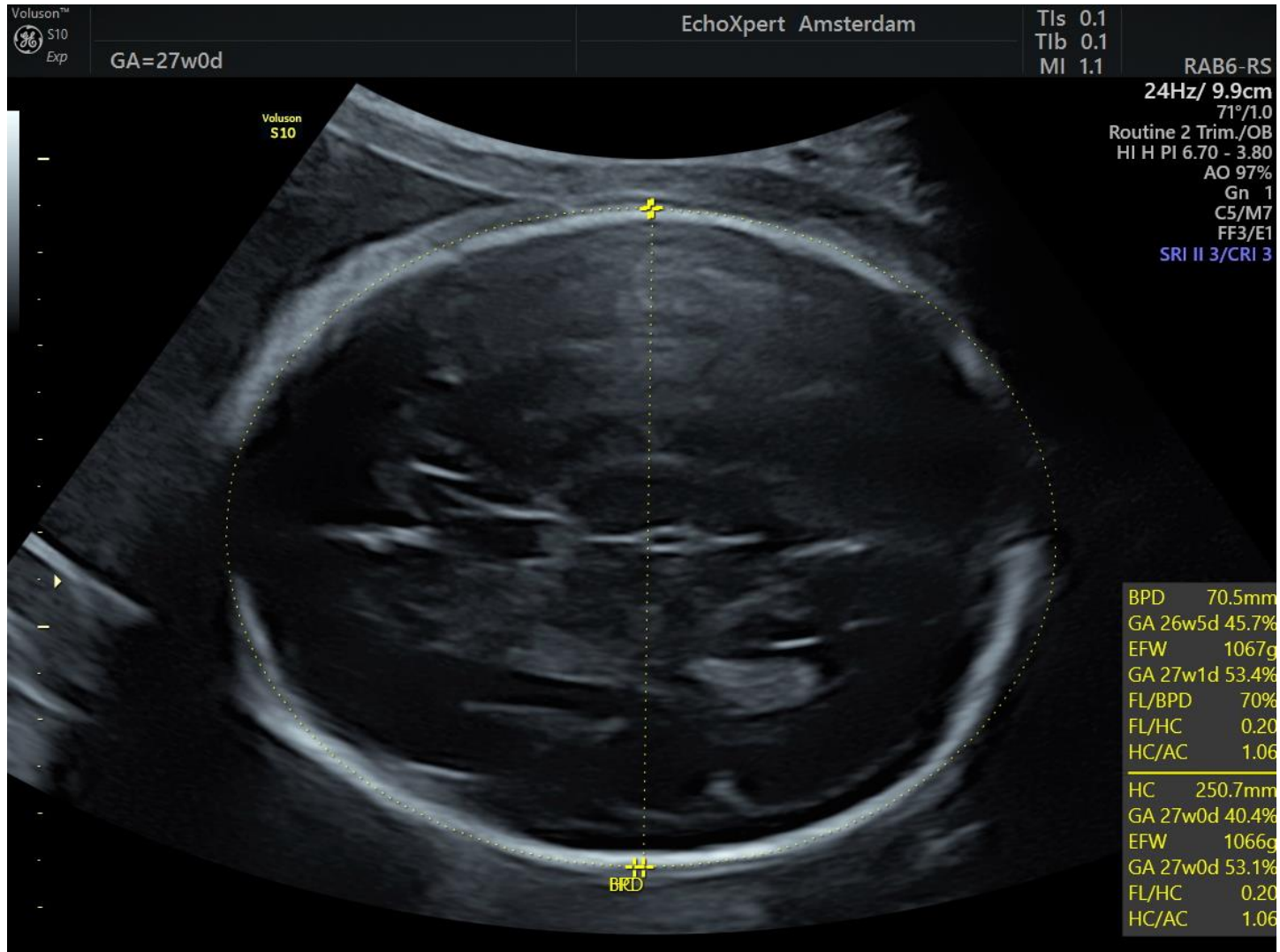
Foto 58/61/64



# Biometrie

24-31 wk HC/DBP

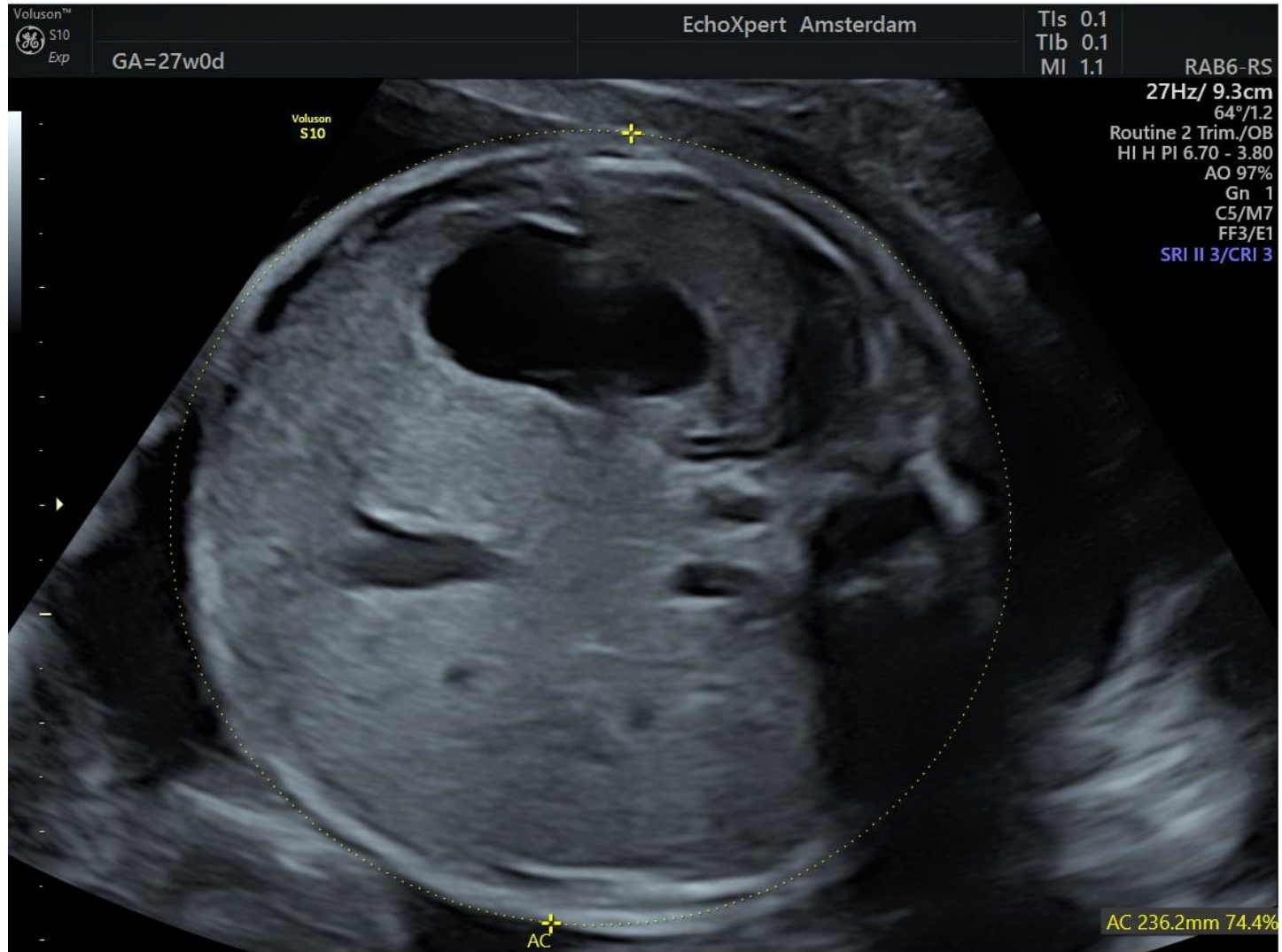
Foto 65/68/71



# Biometrie

24-31 wk AC

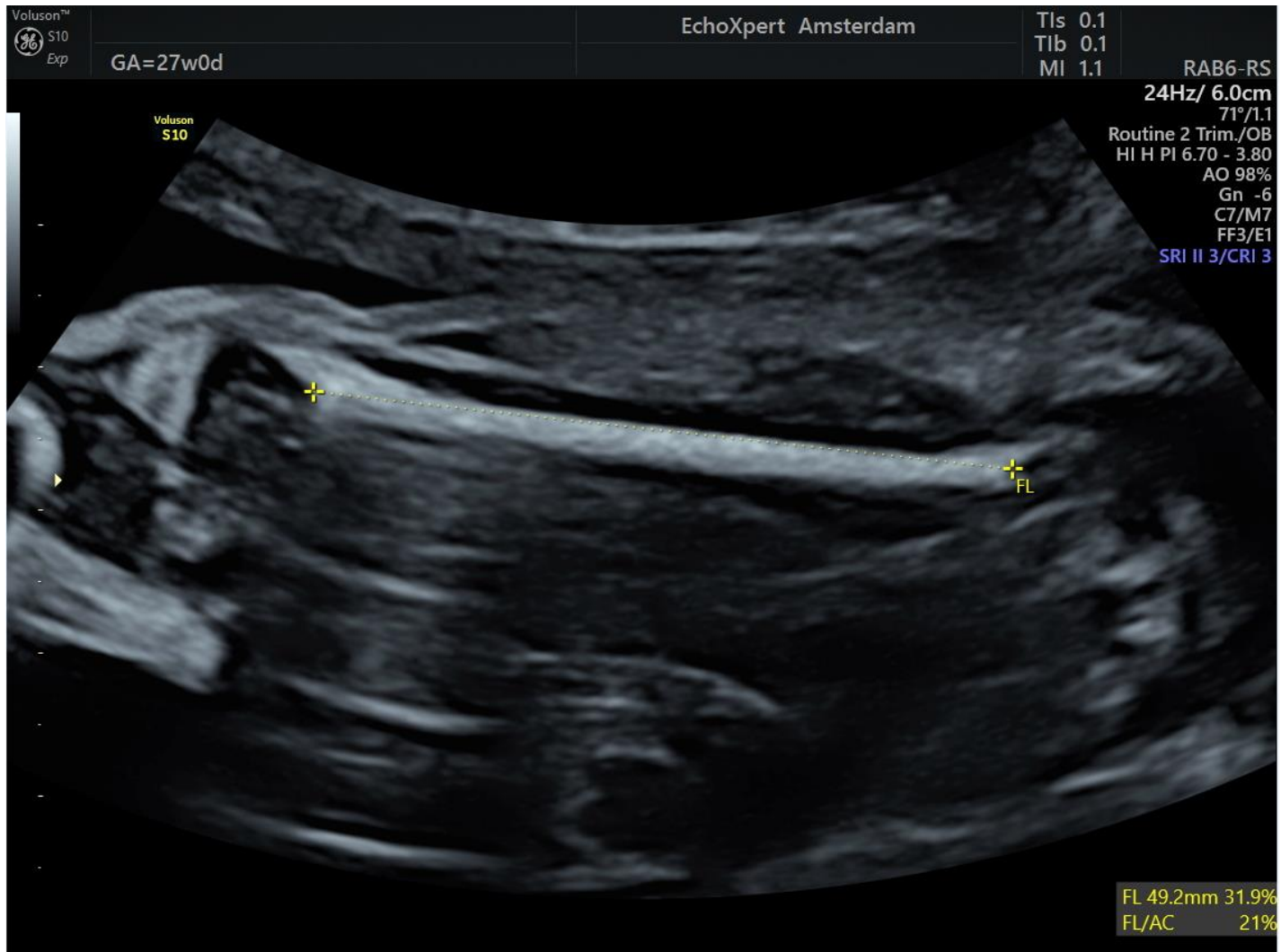
Foto 66/69/72



# Biometrie

24-31 wk FL

Foto 67/70/73

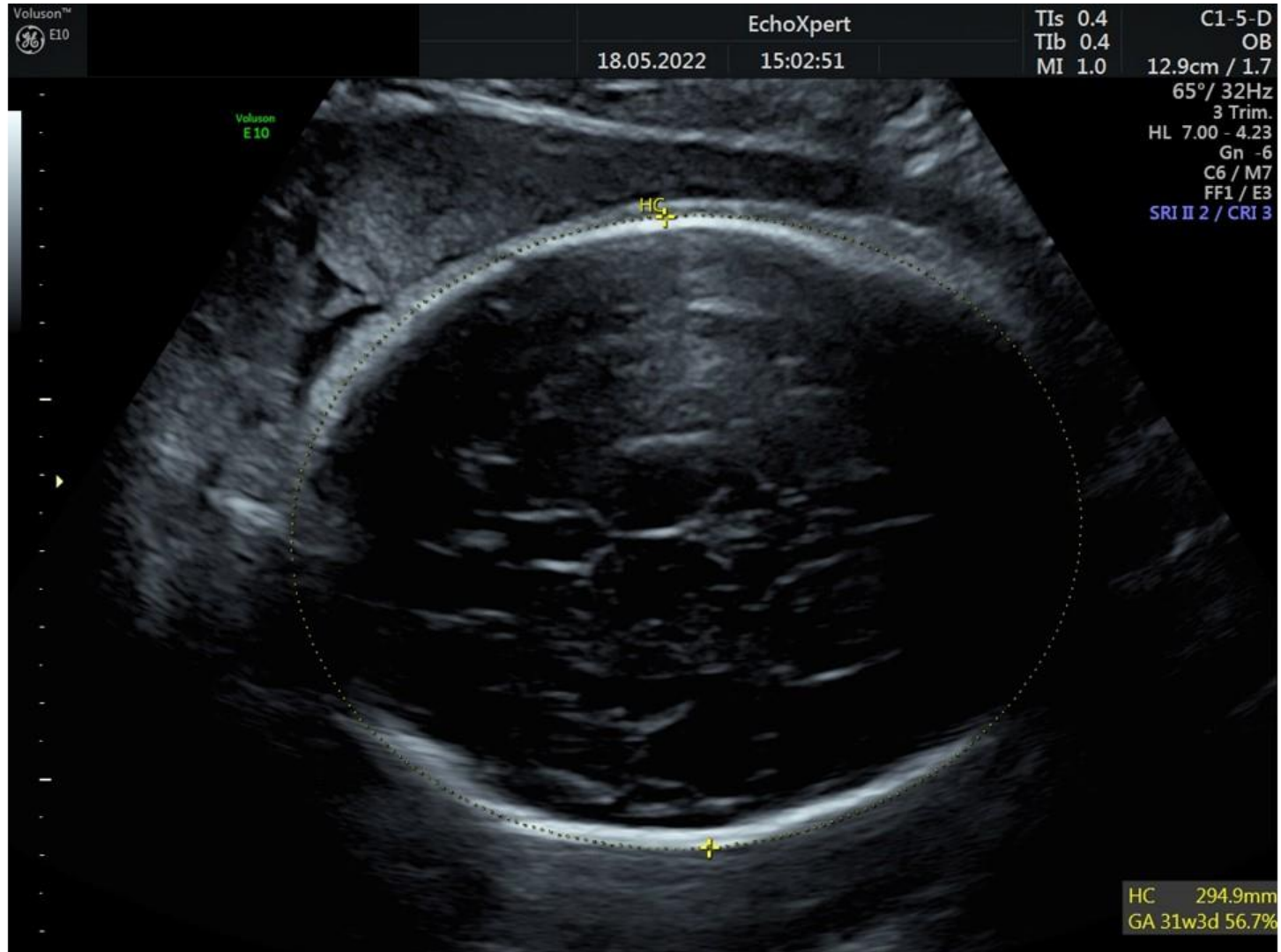




# Biometrie

31-35 HC/DBP

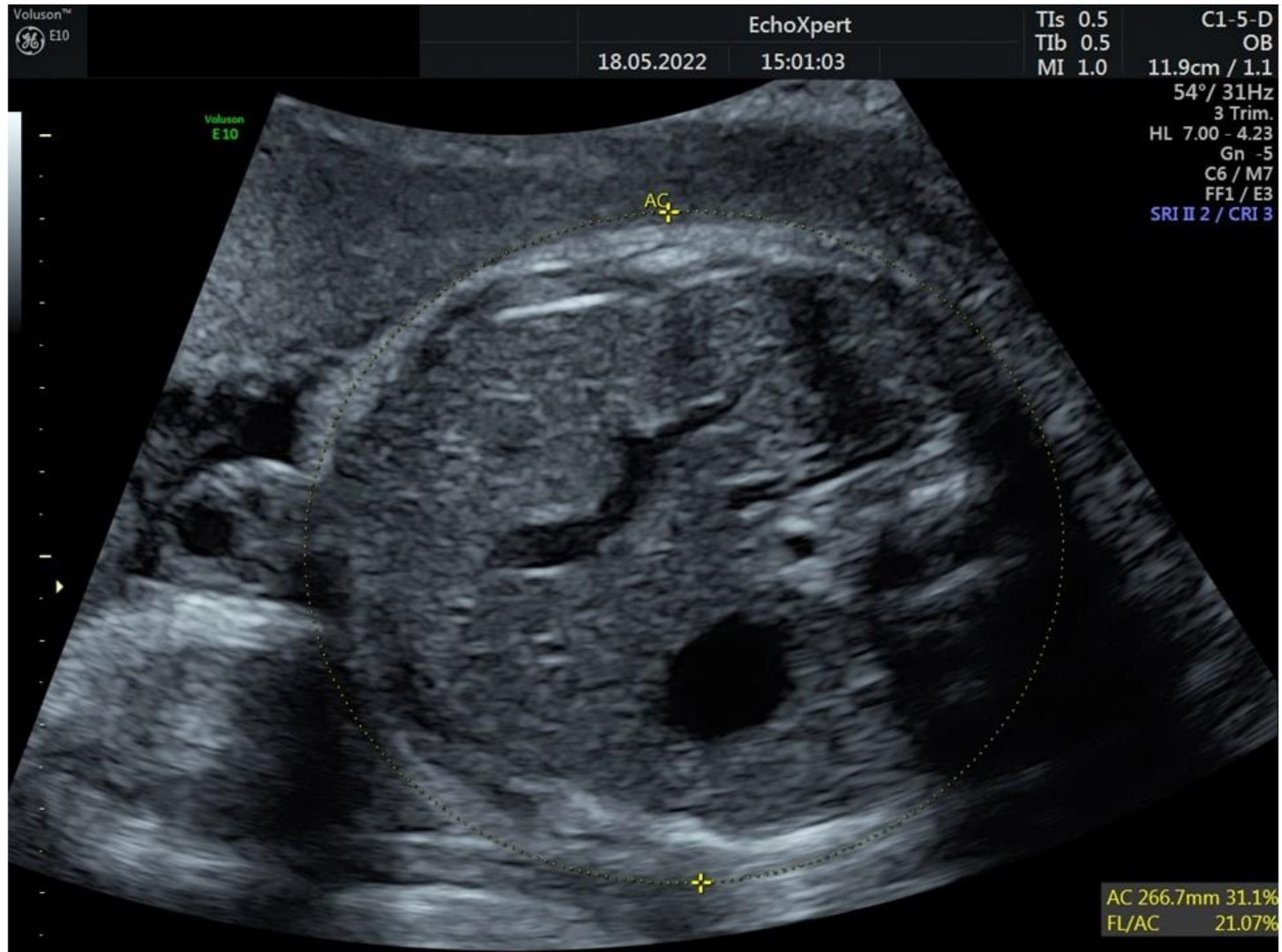
Foto 74/77/80



# Biometrie

31-35 wk AC

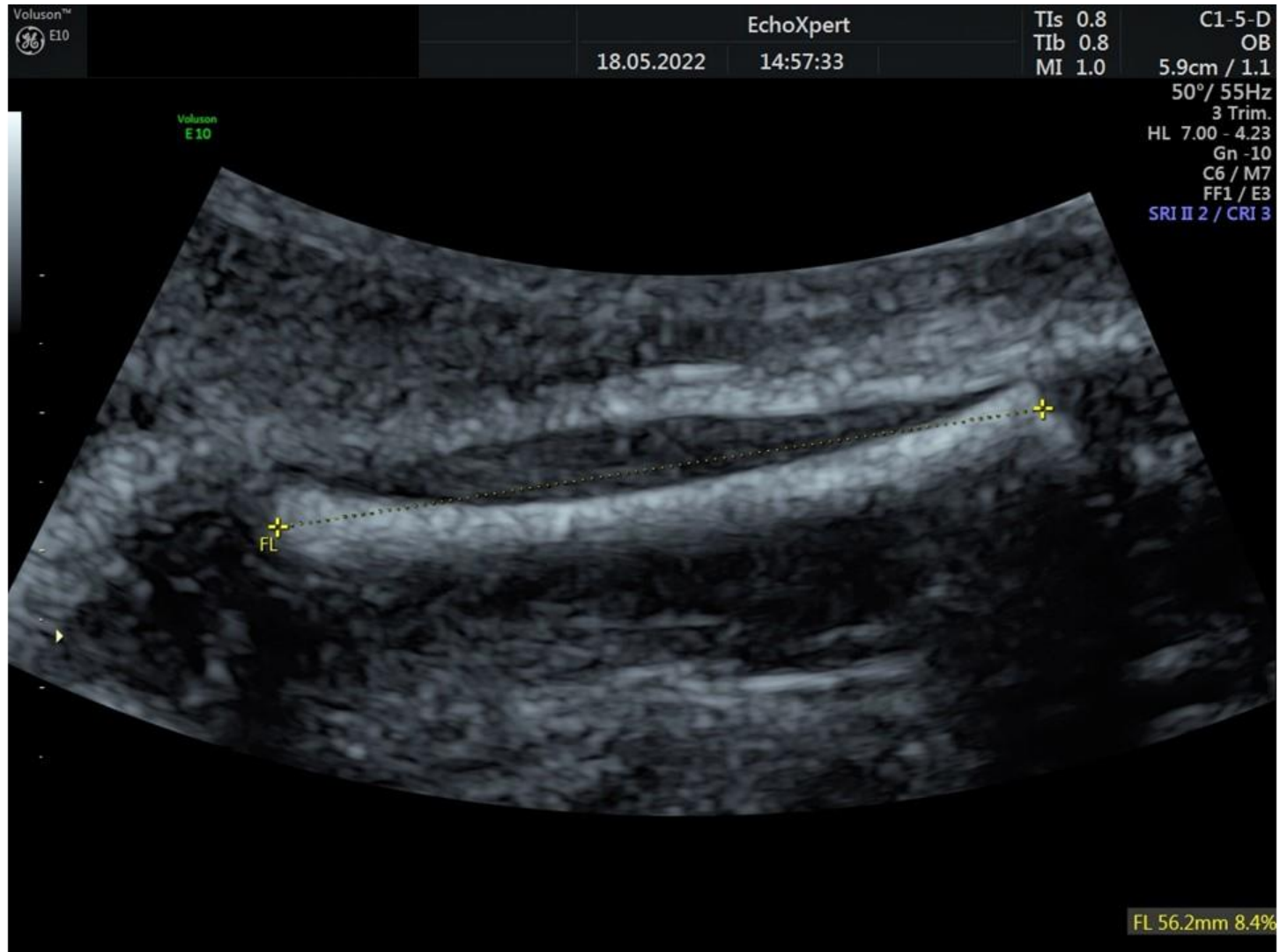
Foto 75/78/81



# Biometrie

31-35 wk FL

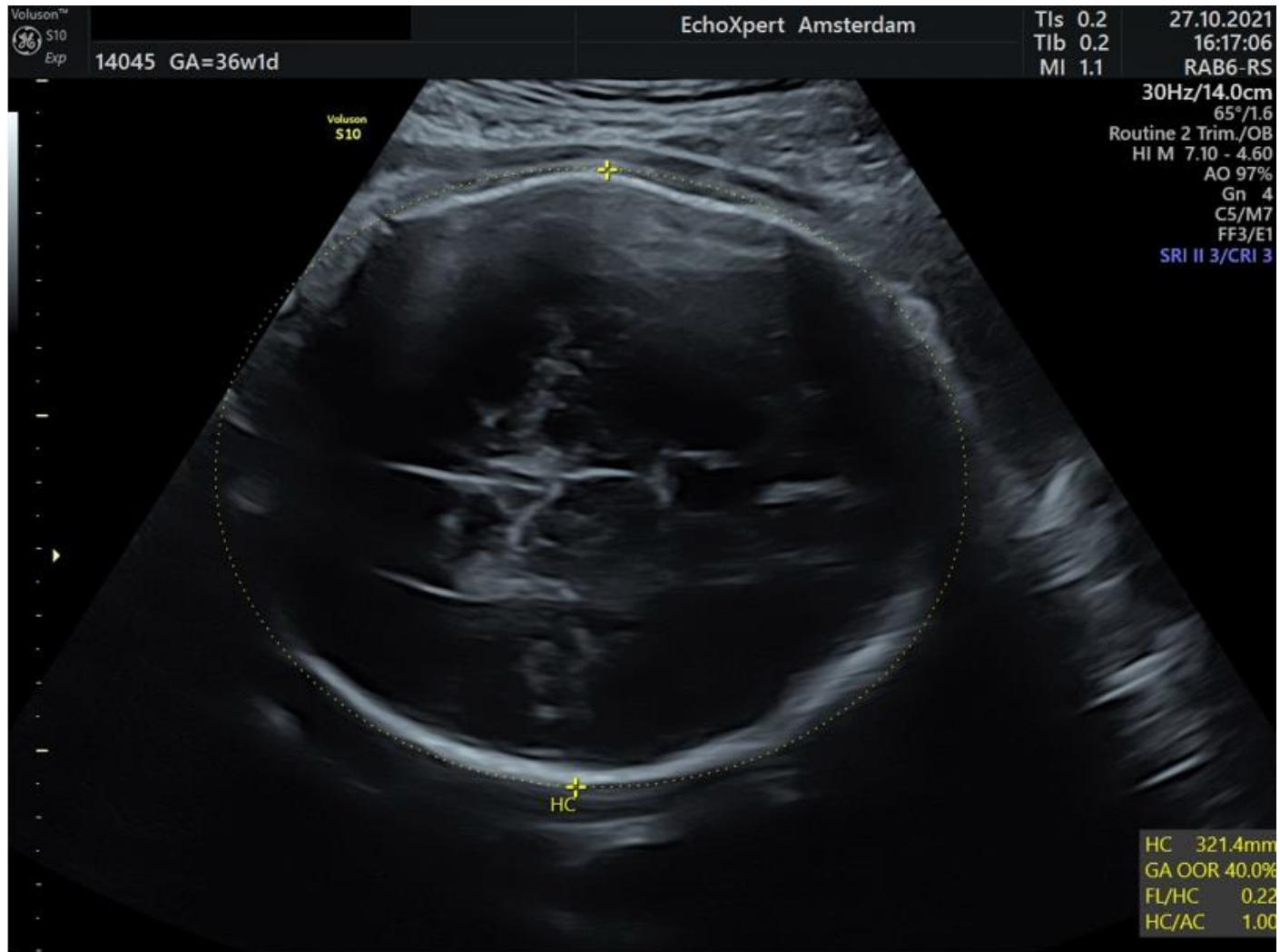
Foto 76/79/82



# Biometrie

33-38 wk HC/DBP

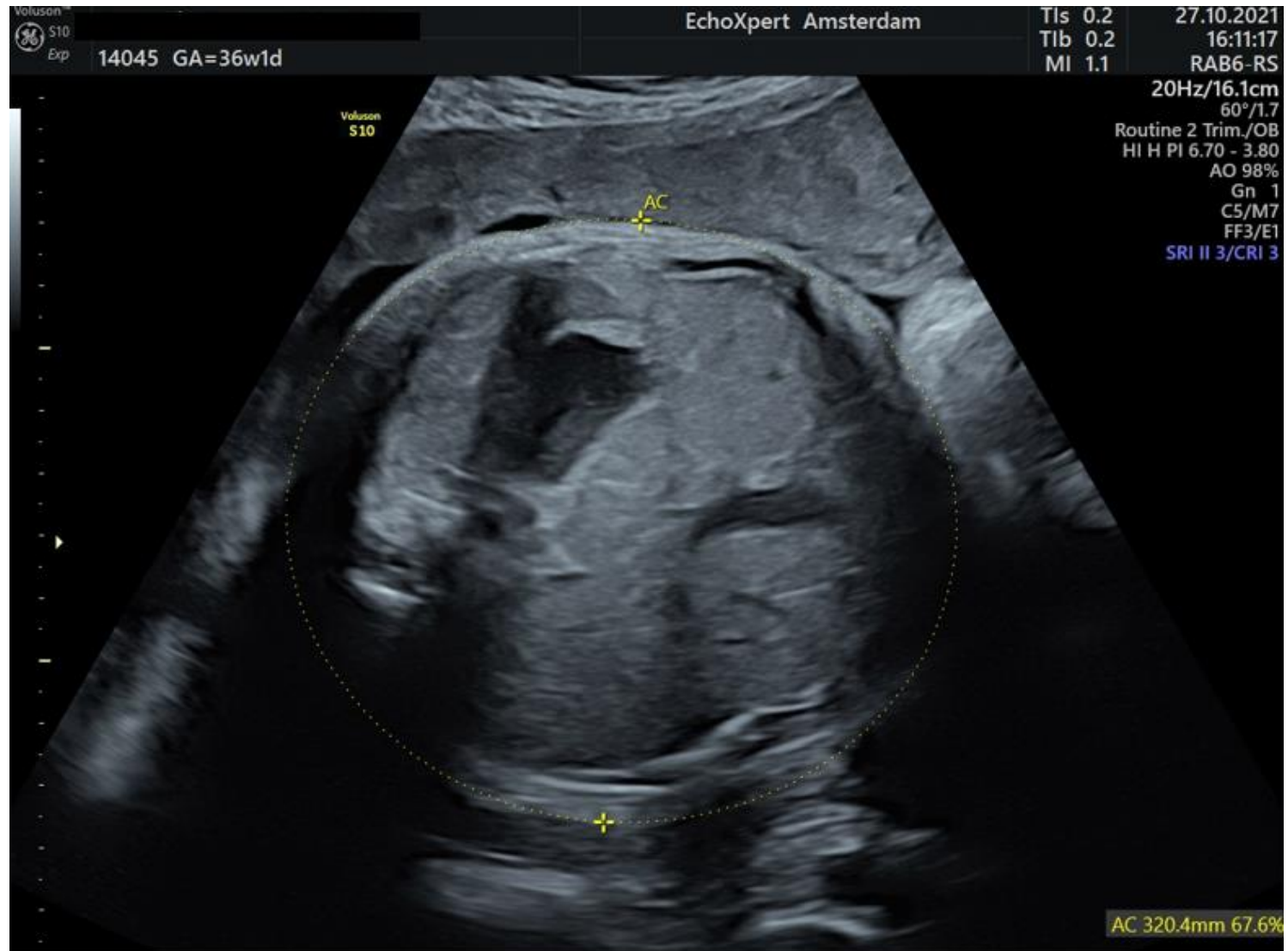
Foto 83



# Biometrie

35-38 wk AC

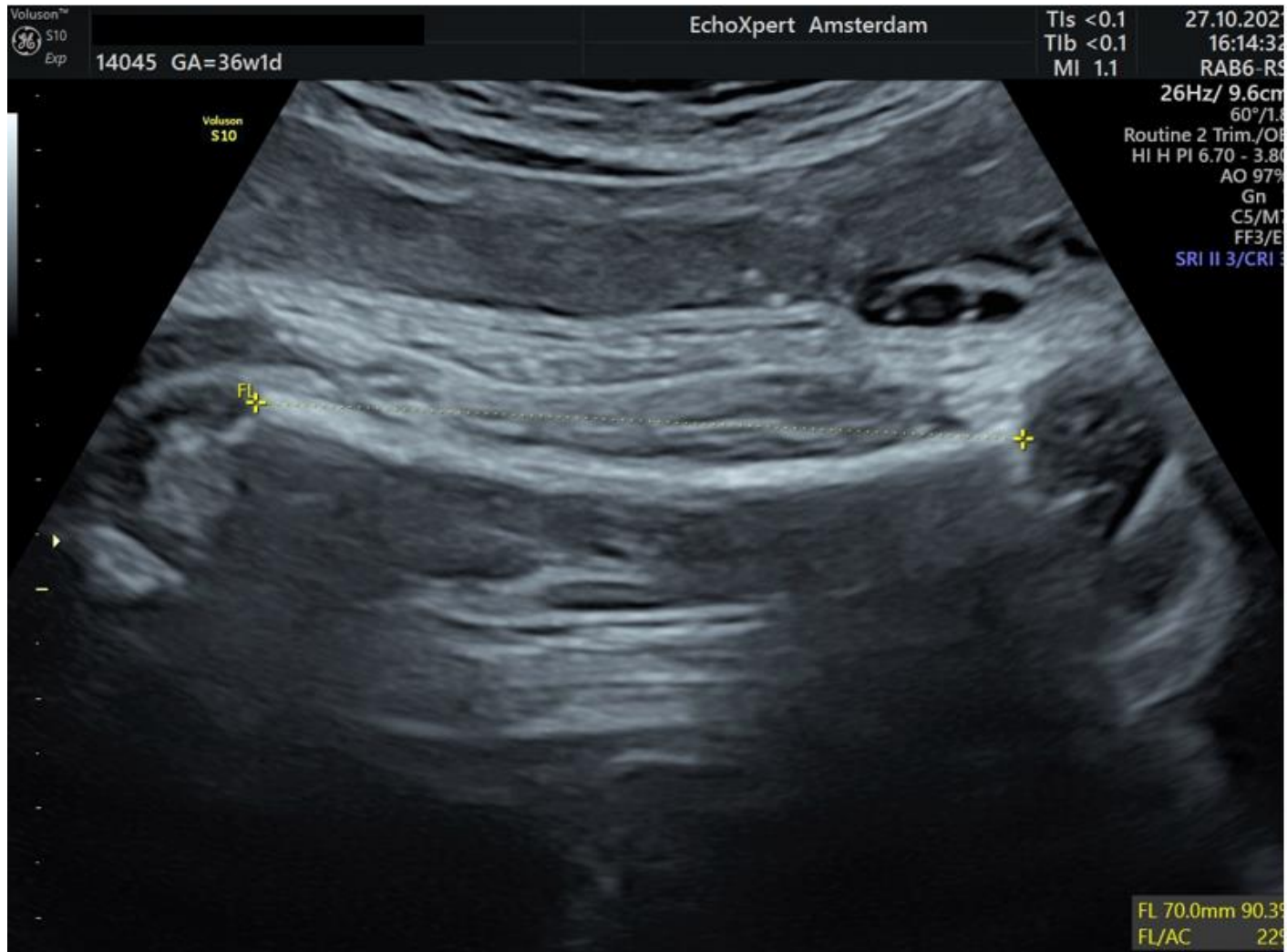
Foto 84



# Biometrie

35-38 wk FL

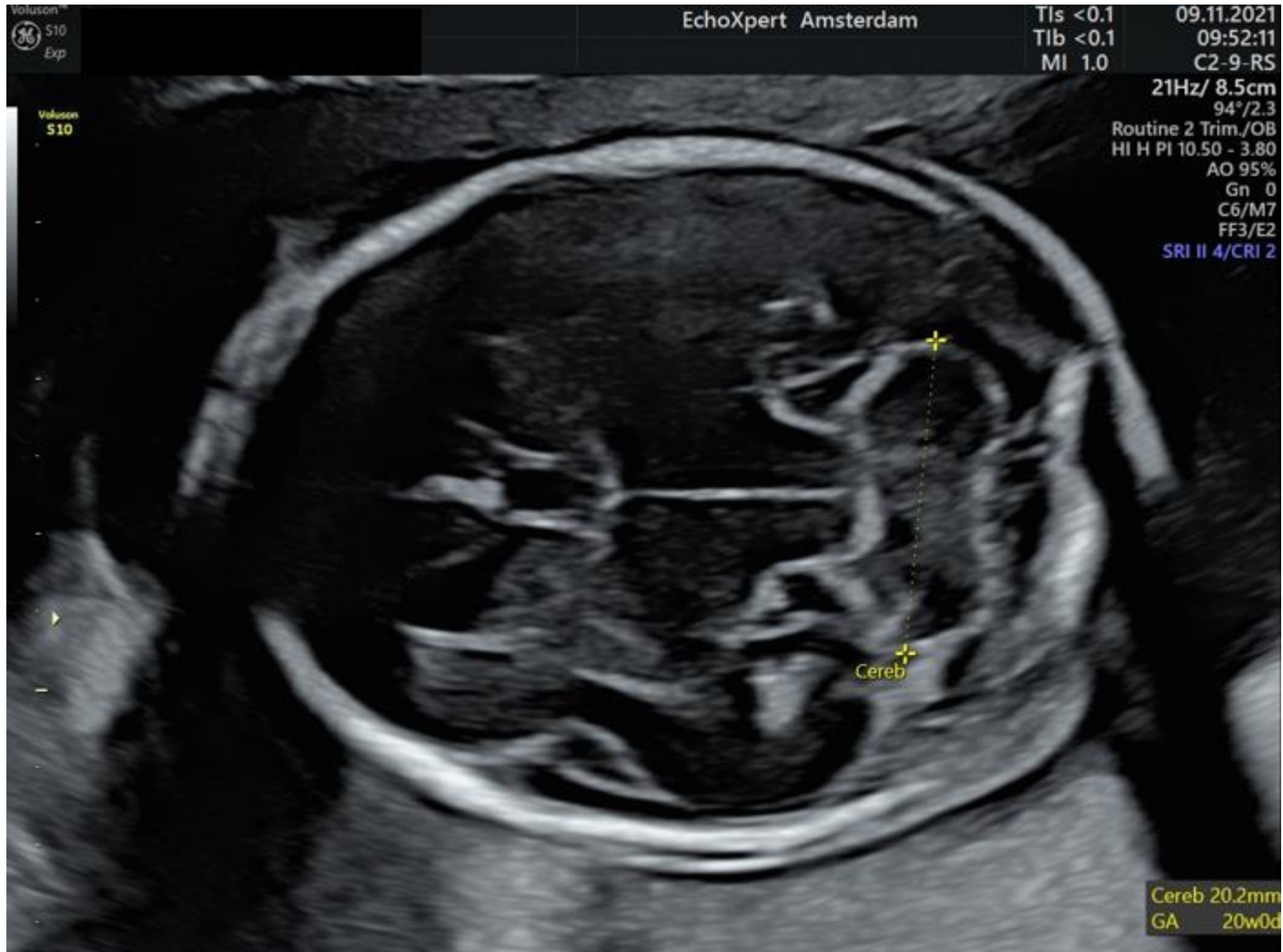
Foto 85



# Biometrie

18-24 wk TCD

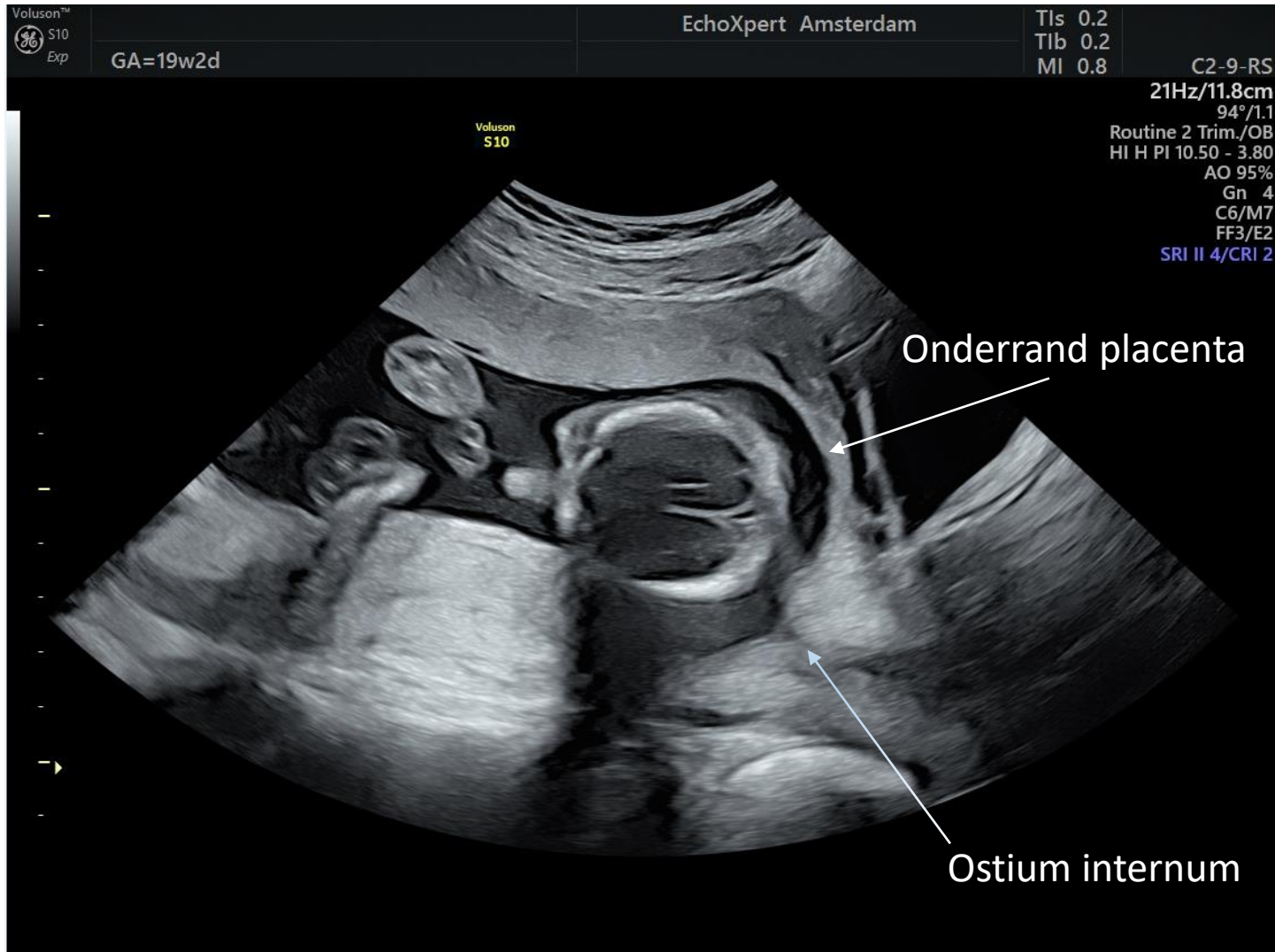
Foto 86/87/88



# Placenta, navelstreng en vruchtwater

Placenta tov ostium internum 18-36 wk (TA)

Foto 89/90

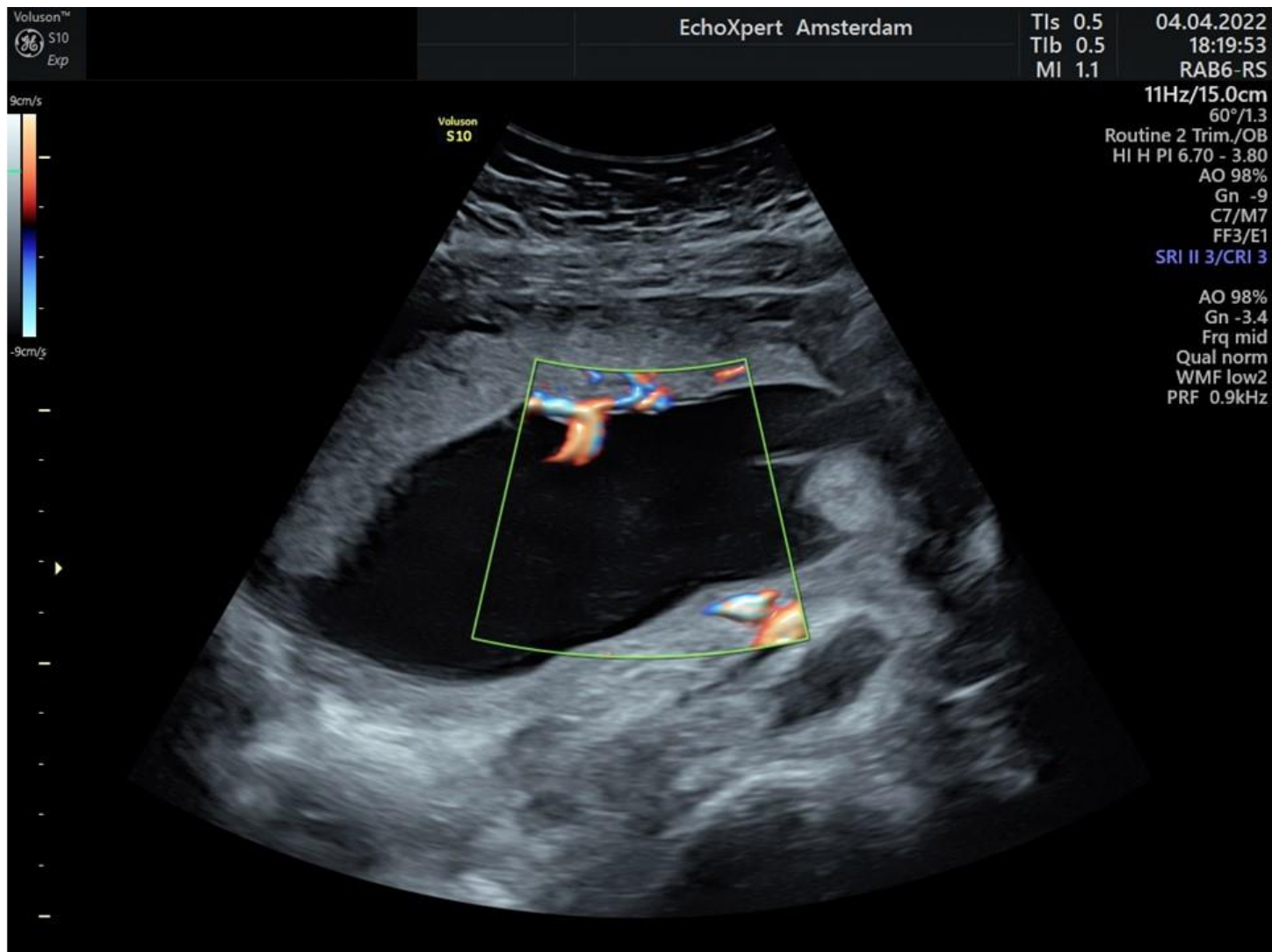




# Placenta, navelstreng en vruchtwater

Navelstrenginsertie in placenta 18-28 wk voorwand (TA)

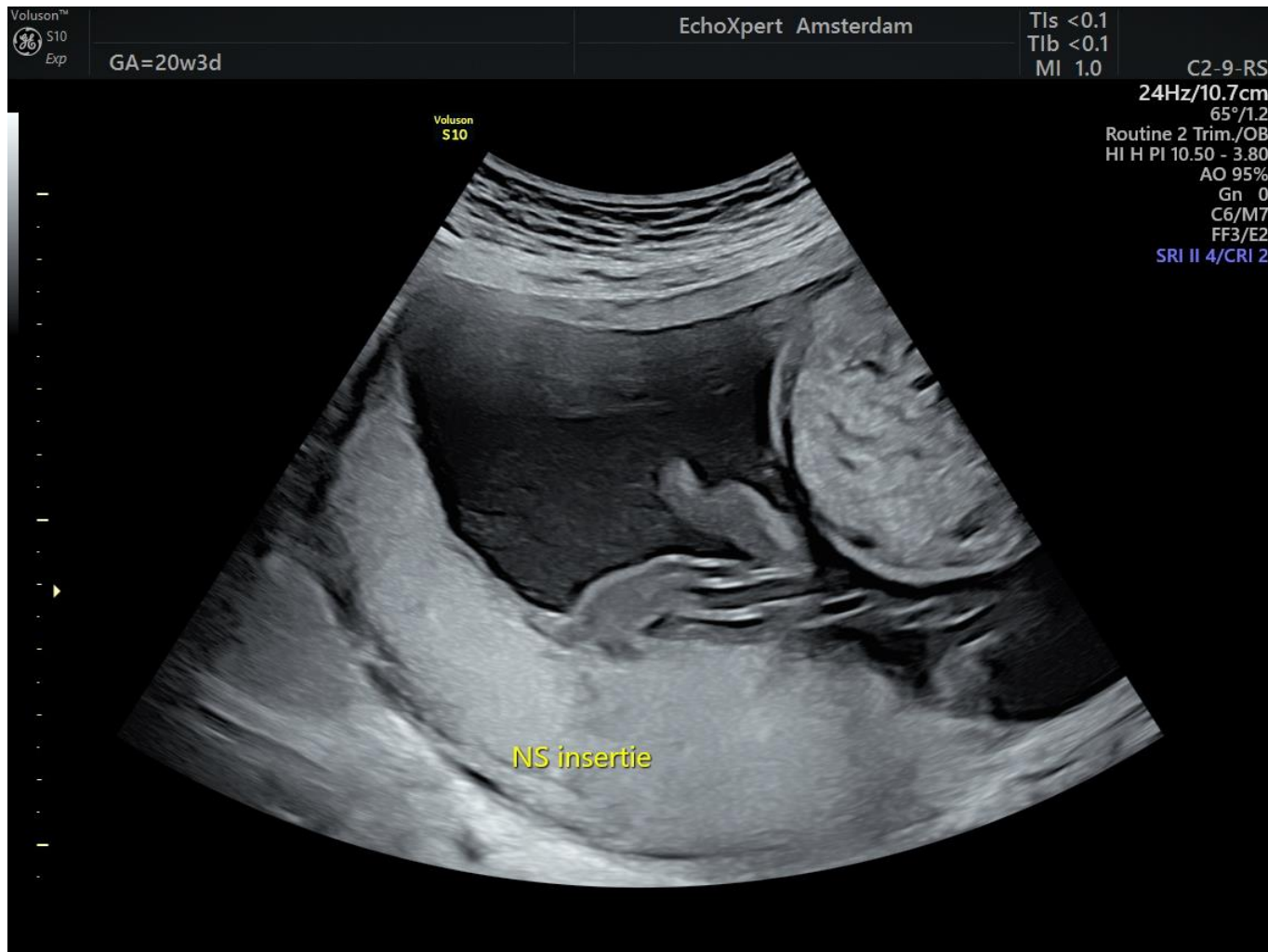
Foto 91



# Placenta, navelstreng en vruchtwater

Navelstrenginsertie in placenta 18-28 wk achterwand (TA)

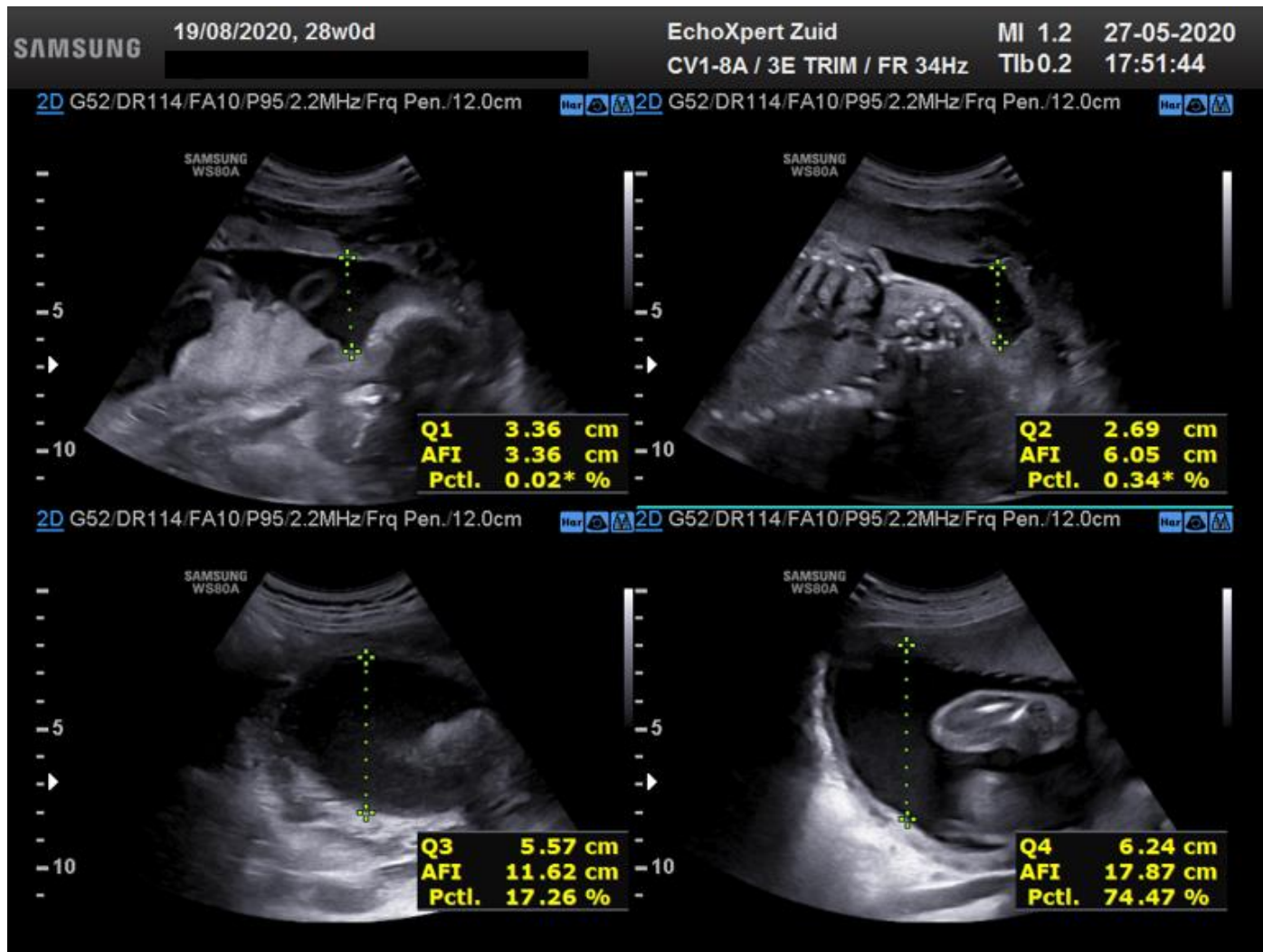
Foto 92



# Placenta, navelstreng en vruchtwater

Hoeveelheid vruchtwater 28-36 wk AFI-meting

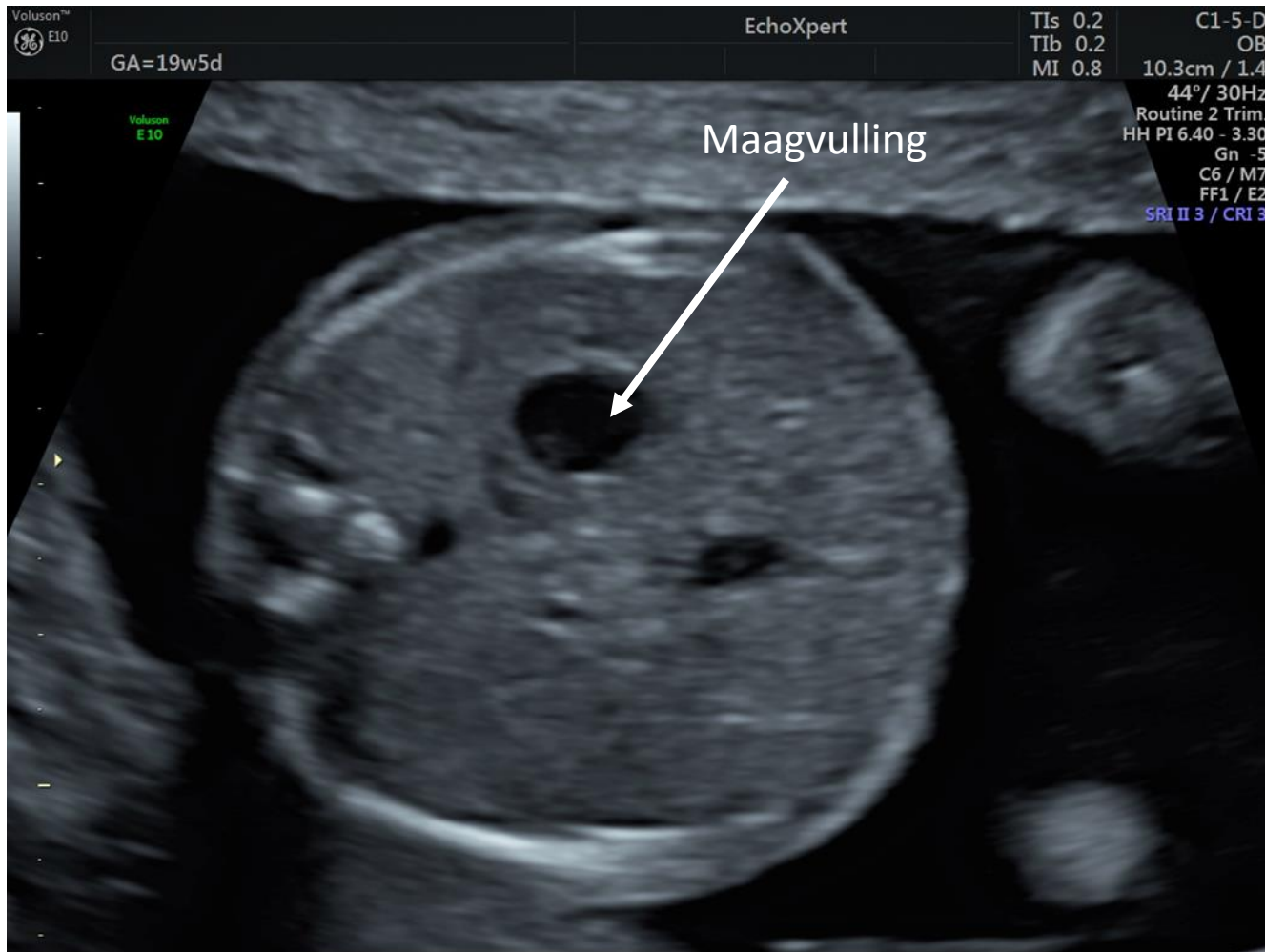
Foto 93/94



# Foetale structuren

18-24 wk maagvulling

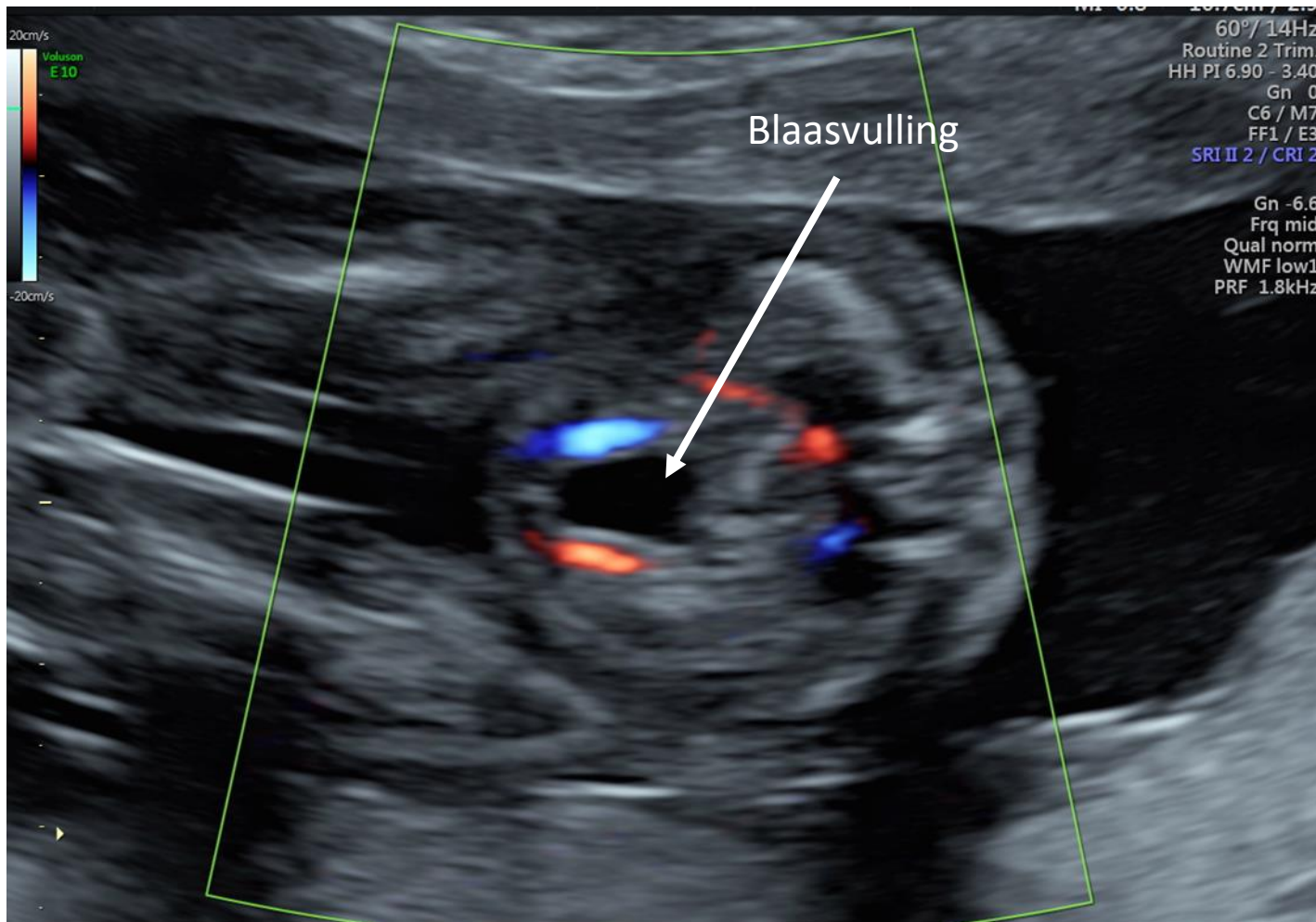
Foto 95



# Foetale structuren

18-24 wk blaasvulling

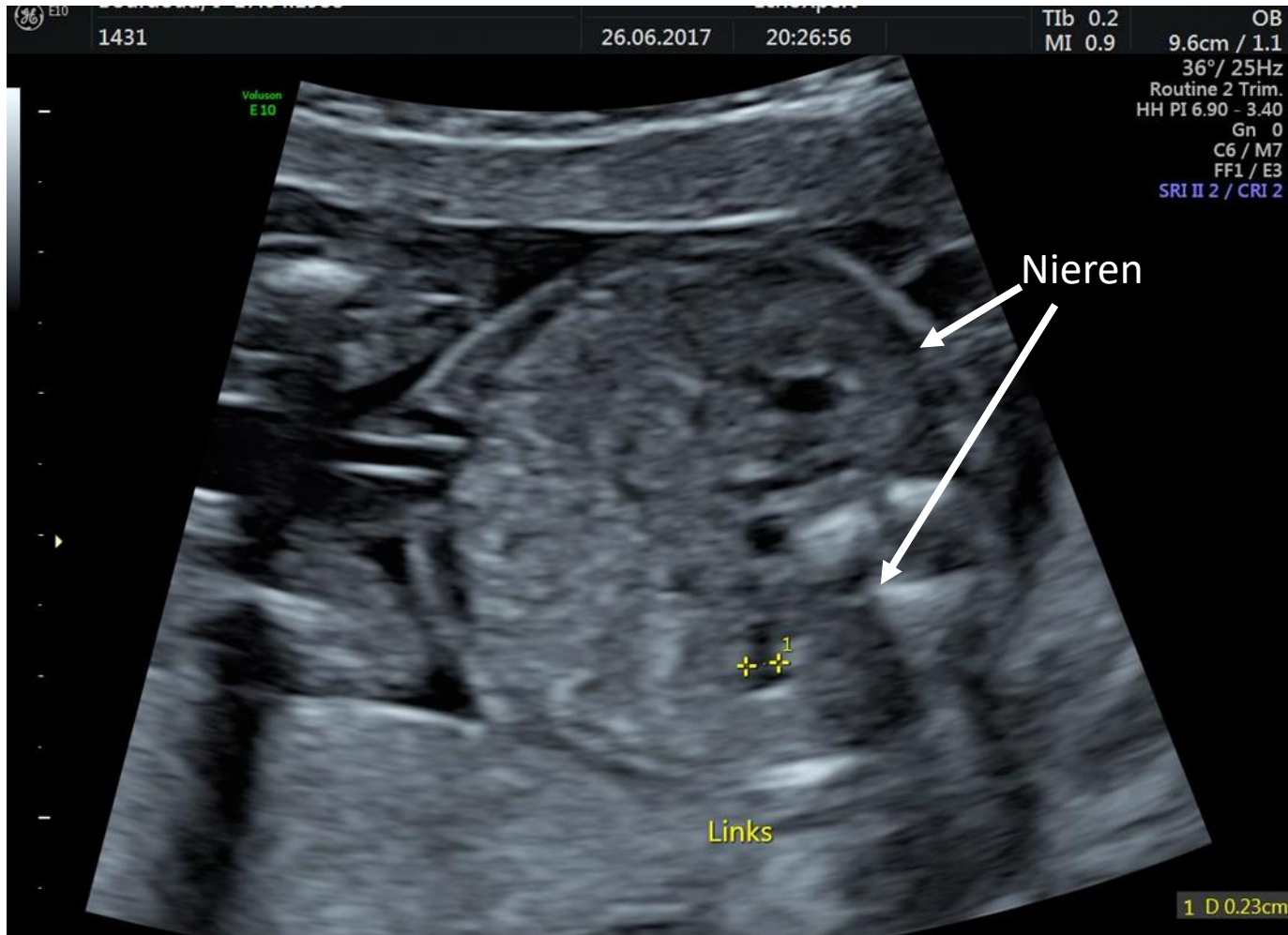
Foto 96



# Foetale structuren

18-24 wk nieren (mag in 2 foto's)

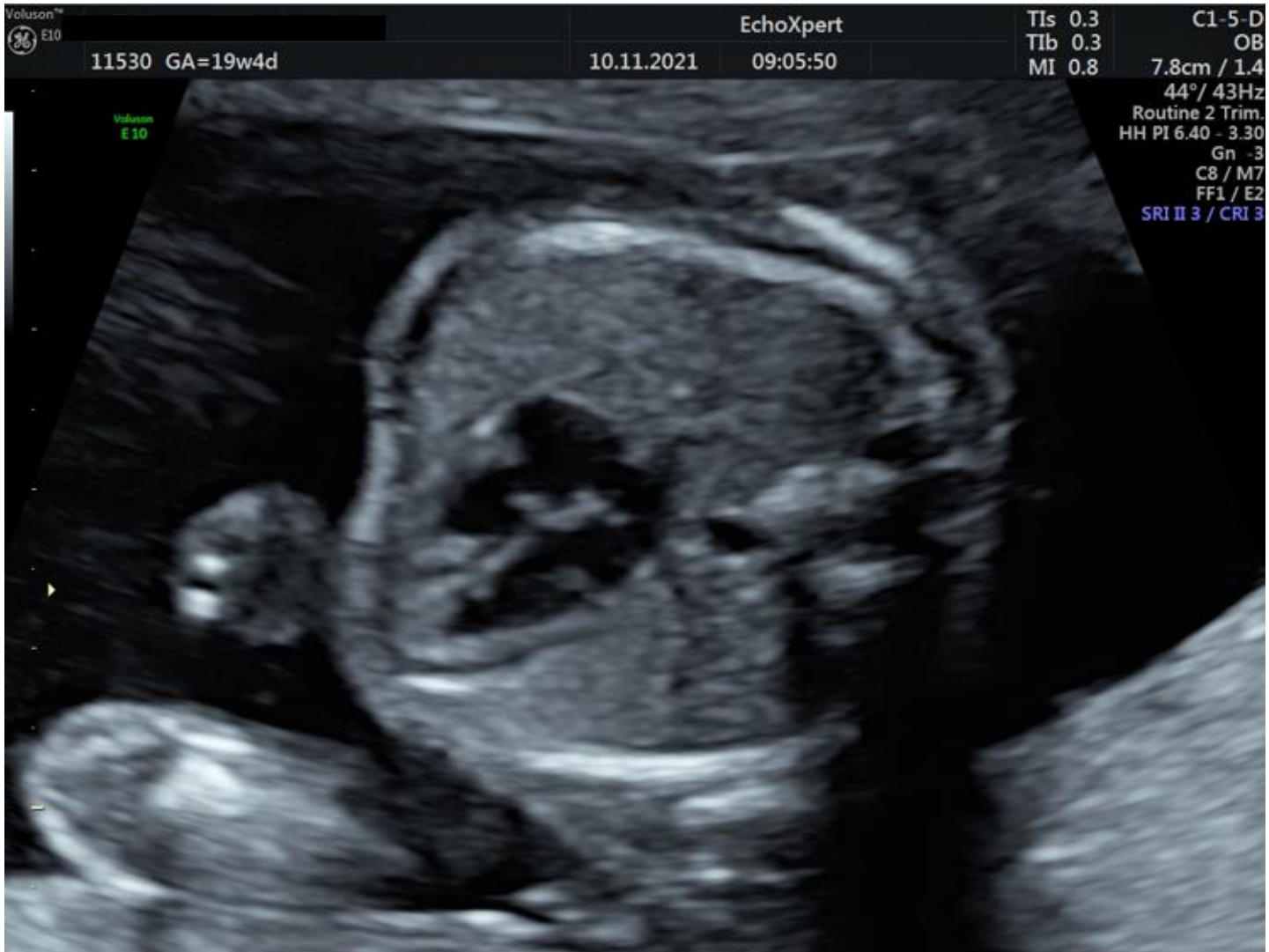Foto 97



# Foetale structuren

18-24 wk 4 kamerbeeld

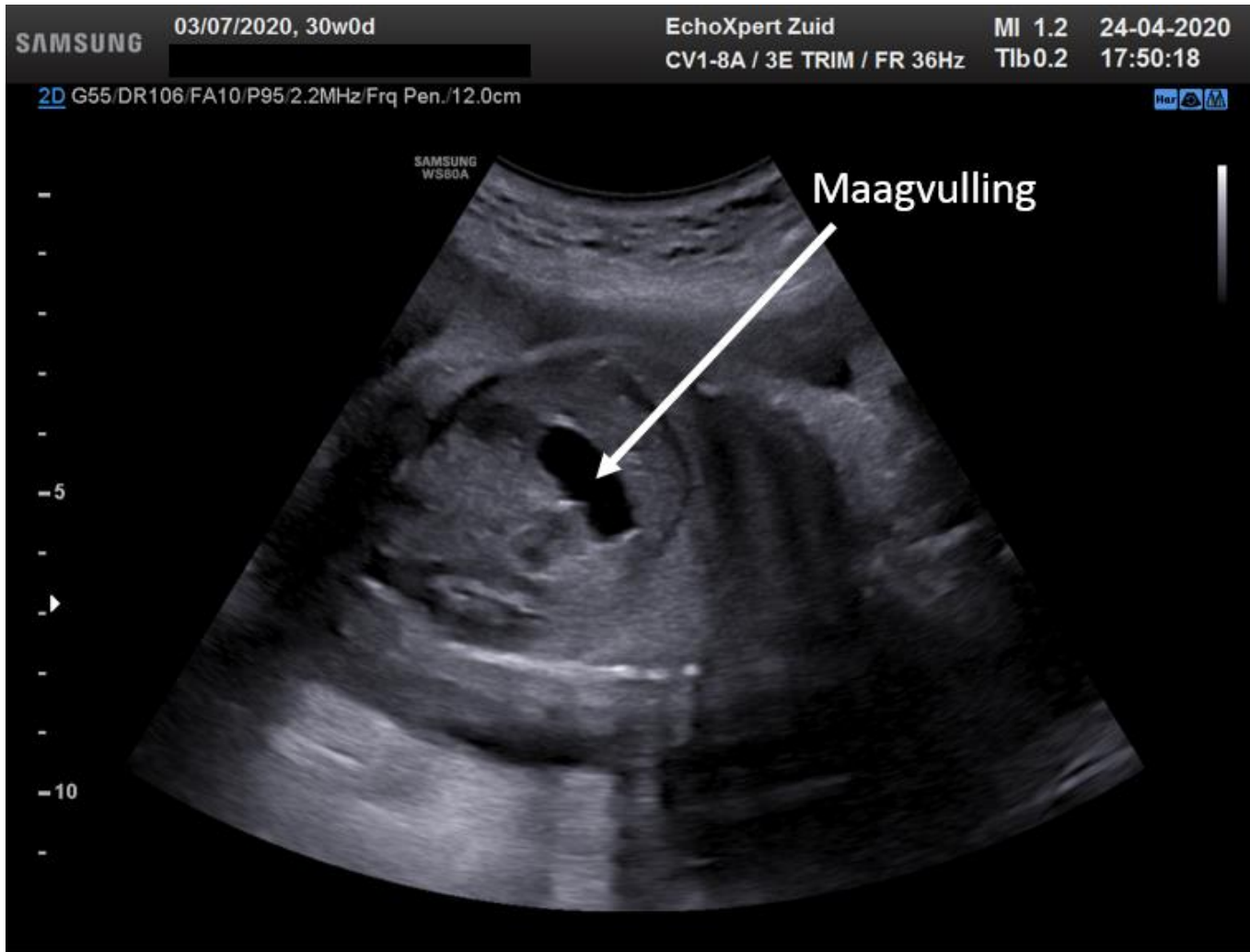
Foto 98



# Foetale structuren

24-31 wk maagvulling

Foto 99

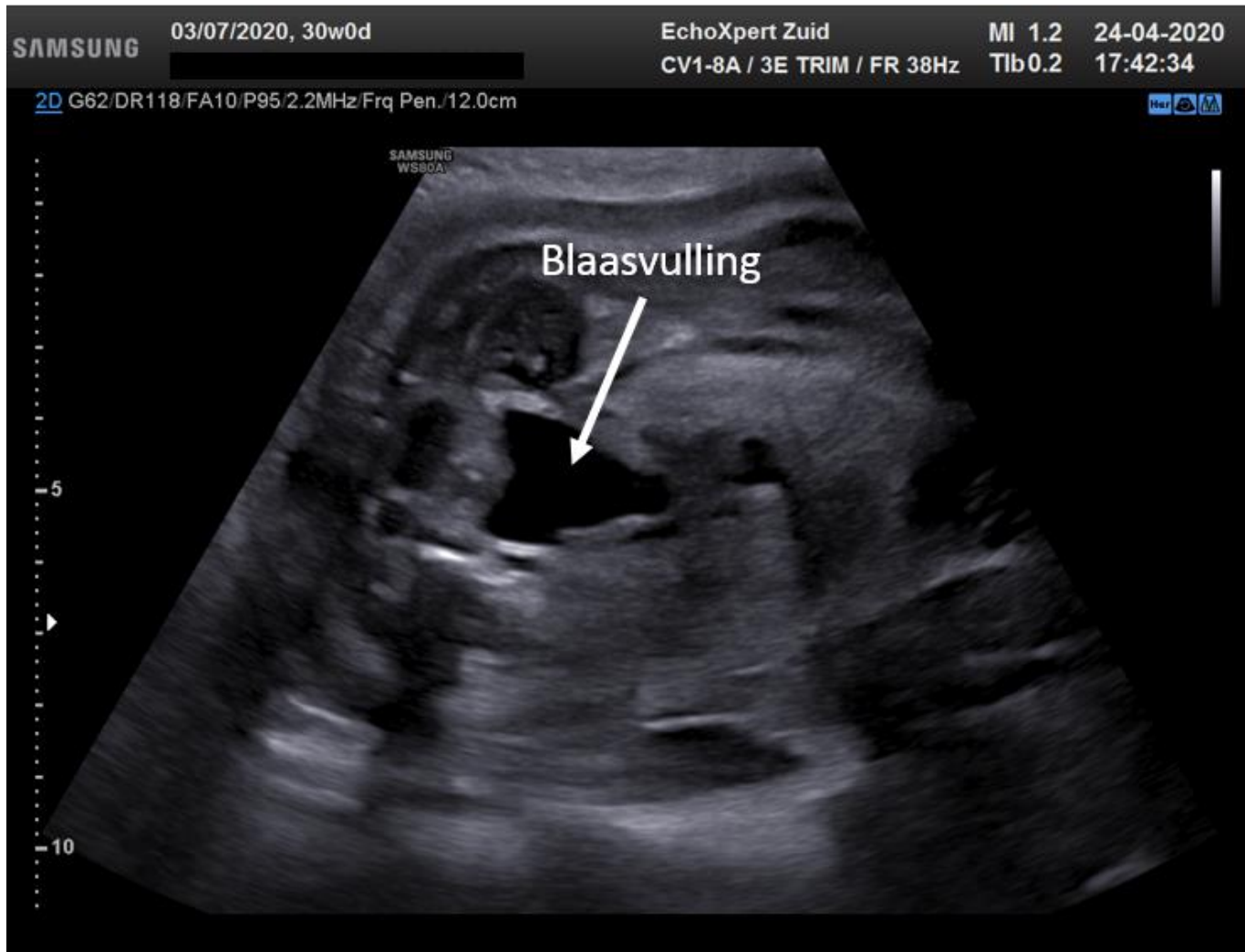



# Foetale structuren

24-31 wk blaasvulling coronaal

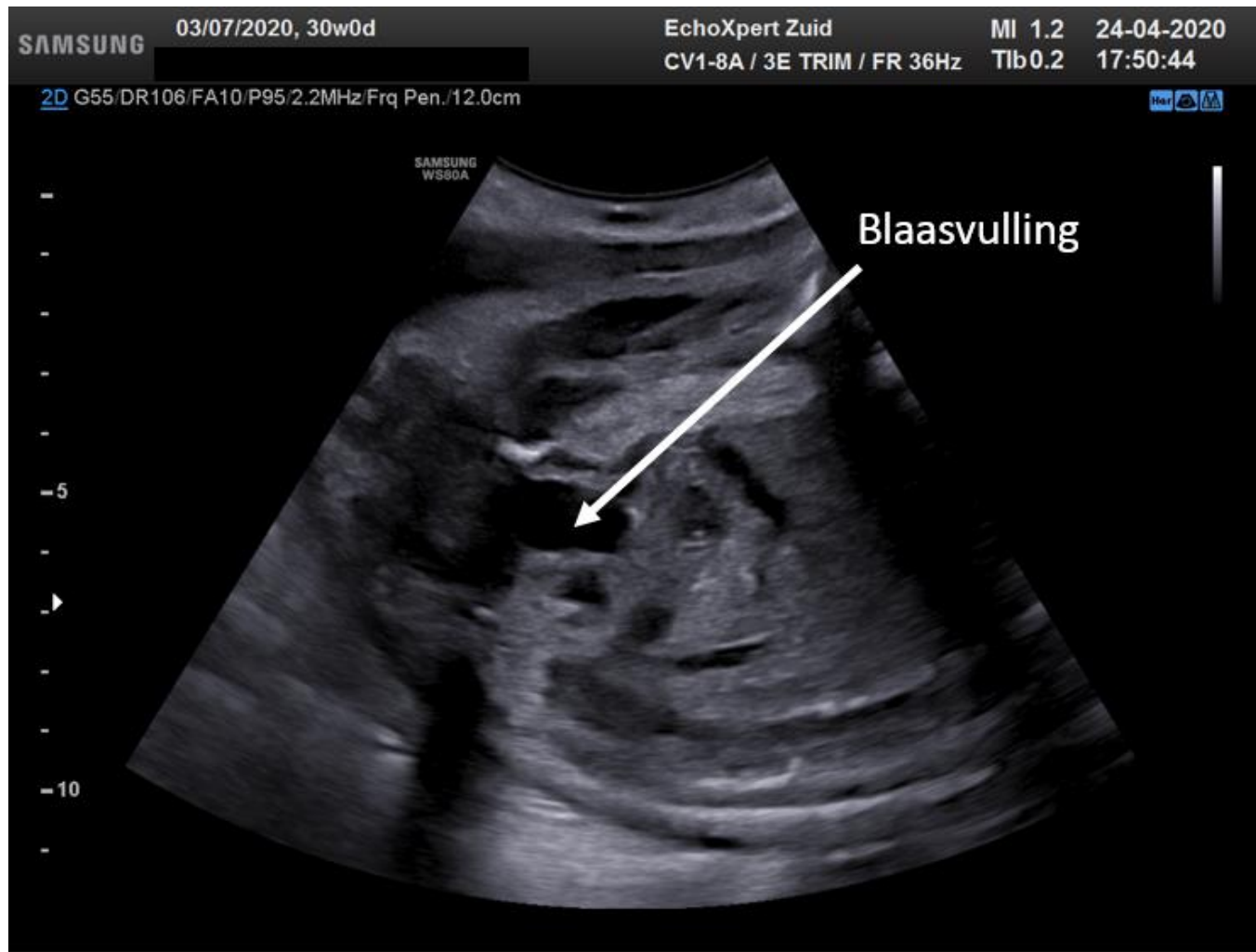
Foto 100



# Foetale structuren

24-31 wk blaasvulling sagittaal

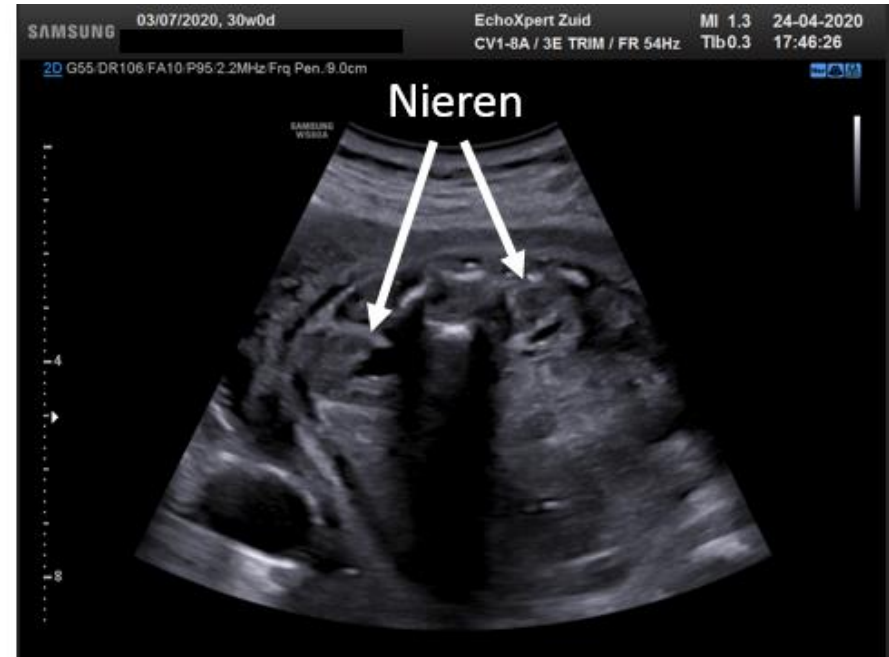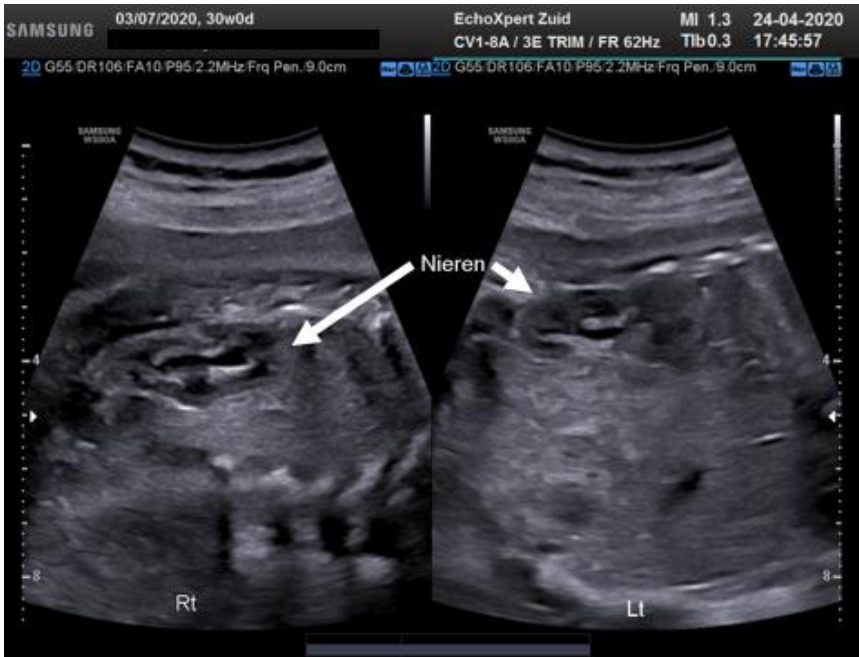Foto 100



# Foetale structuren

24-31 wk nieren (mag in 2 foto's)

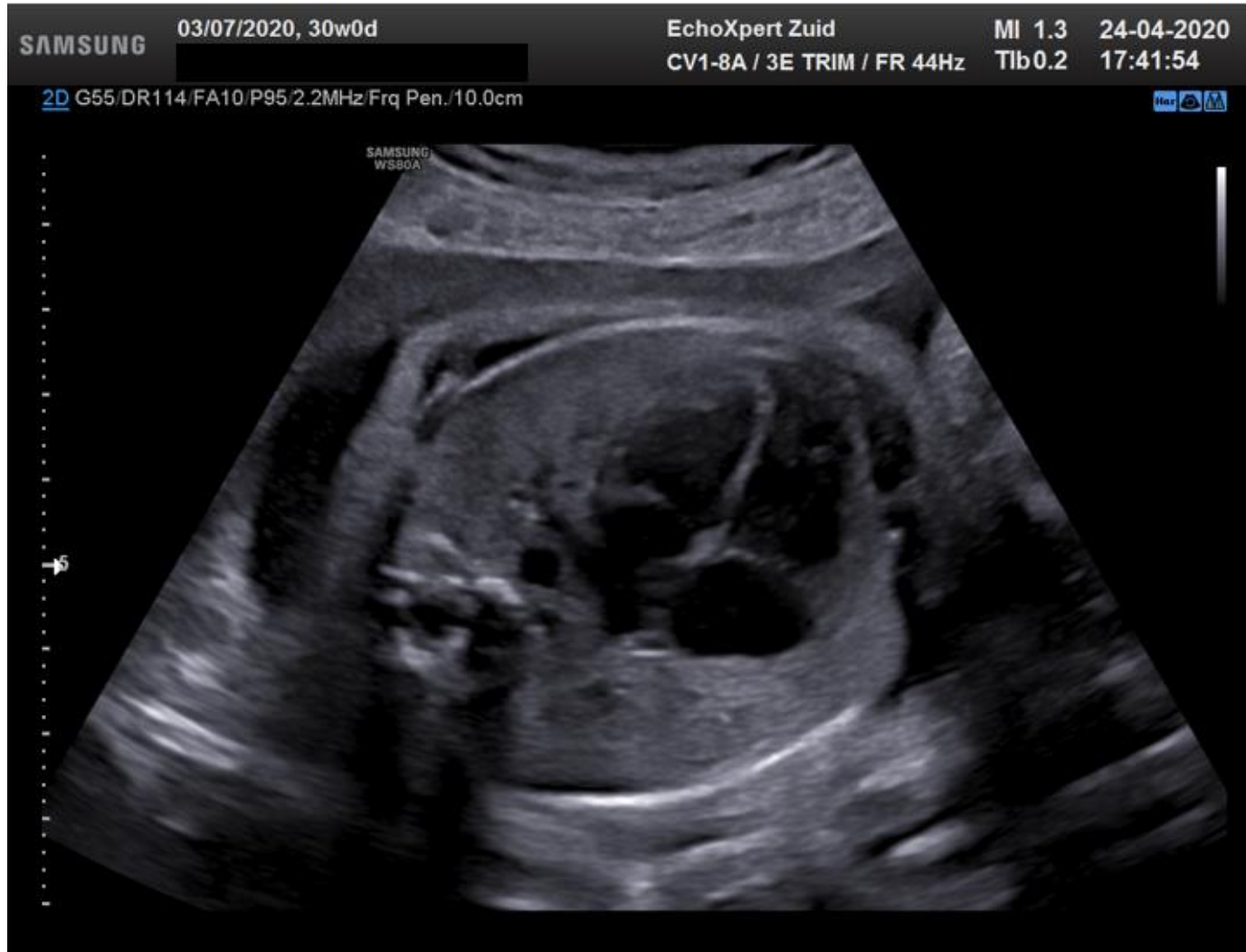Foto 101



# Foetale structuren

24-31 wk 4-kamerbeeld

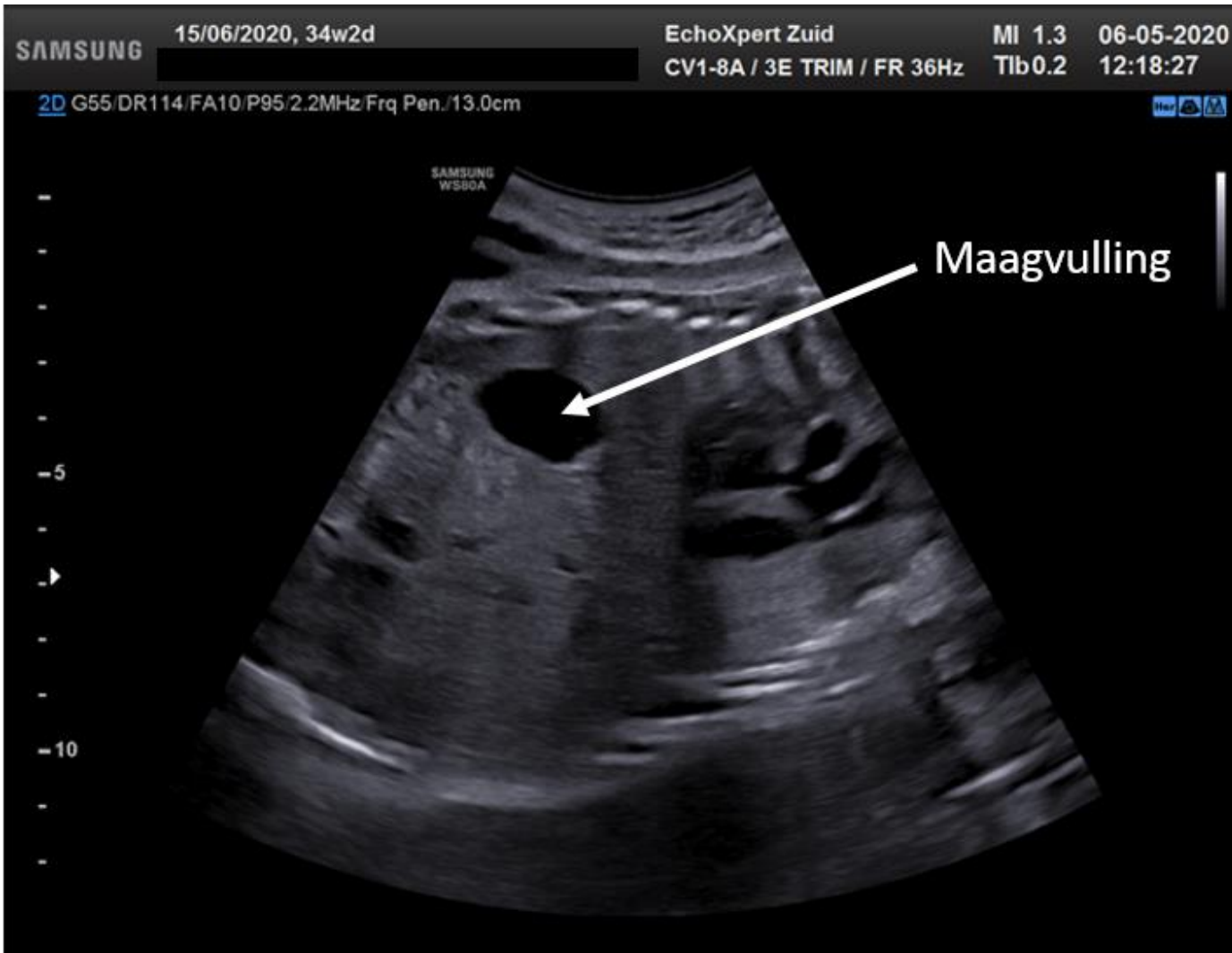
Foto 102



# Foetale structuren

31-35 wk maagvulling

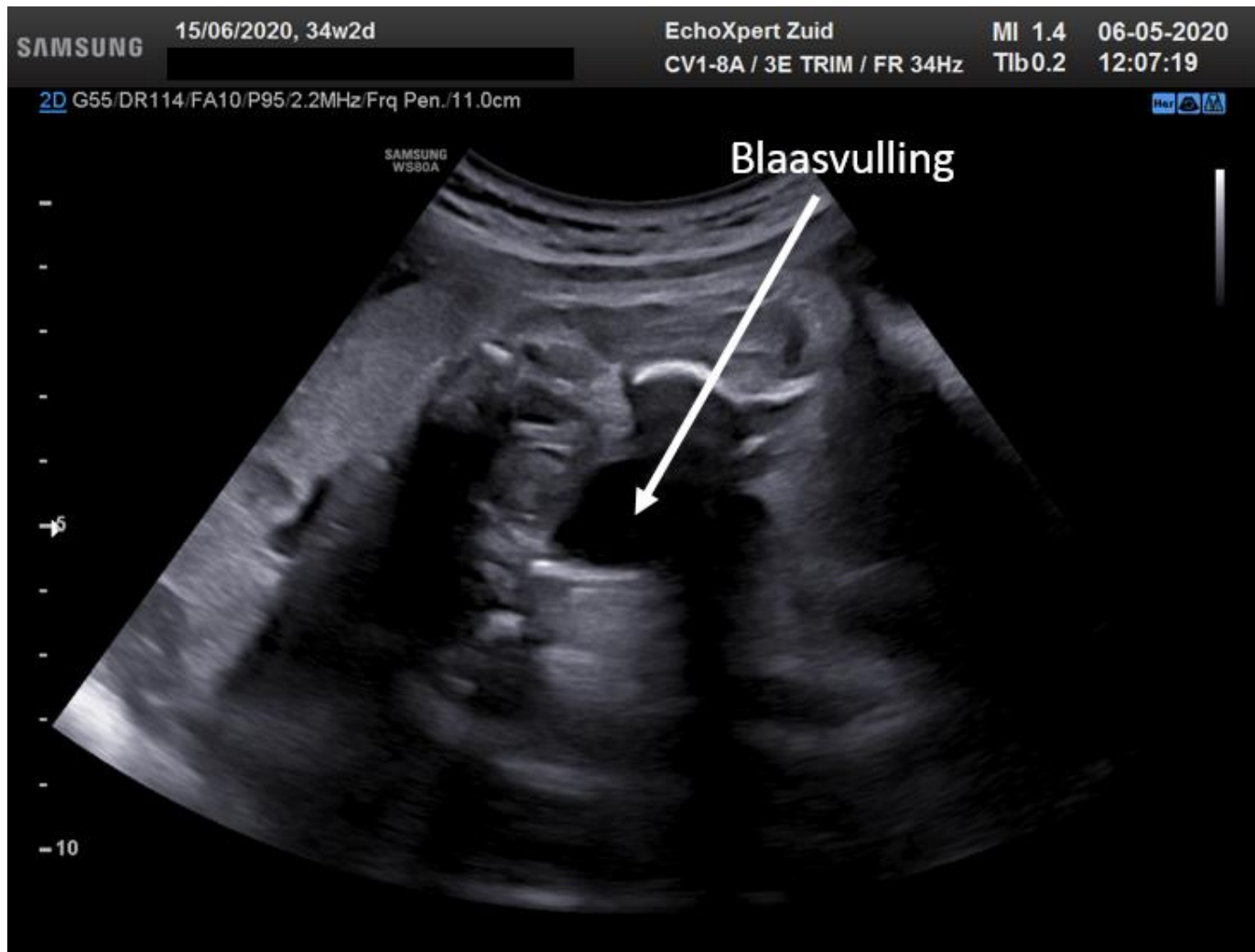
Foto 103



# Foetale structuren

31-35 wk blaasvulling

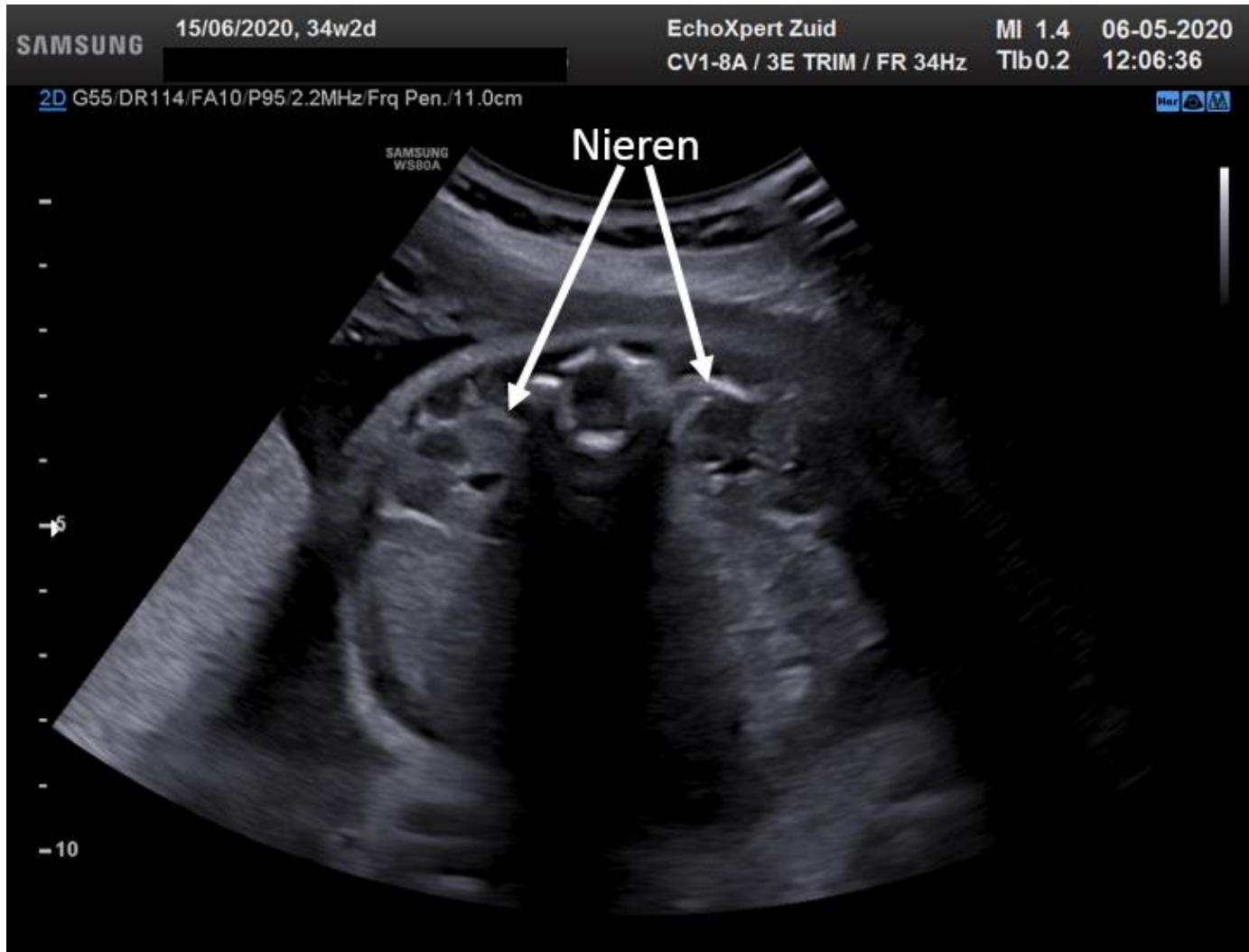
Foto 104



# Foetale structuren

31-35 wk nieren (mag in 2 foto's)

Foto 105



# Foetale structuren

31-35 wk 4-kamerbeeld

Foto 106

